

### Manic Switch in a Patient With Treatment-Resistant Bipolar Depression Treated With Modafinil

**Sir:** A number of prospective open-label studies and case reports and 1 placebo-controlled study (showing a significant effect vs. placebo on the Clinical Global Impressions-Improvement scale and positive trends in affective rating scales) suggest that the novel psychostimulant modafinil might be a useful augmentation treatment for depressive patients who are partially responsive or nonresponsive to antidepressants.<sup>1-5</sup> This finding applies mainly to the unipolar subtype; however, a few cases of bipolar depression are reported.<sup>1-5</sup> No switch into mania to our knowledge has been reported yet with modafinil, in contrast to other antidepressants and psychostimulants. Only 1 case of a narcoleptic adolescent who developed a manic episode under treatment with modafinil has been described so far.<sup>6</sup> Here we report the case of a woman with treatment-resistant bipolar depression who developed a manic syndrome after addition of modafinil.

**Case report.** Ms. A, a 62-year-old woman with a history of DSM-IV bipolar I disorder for 9 years, was admitted to our hospital for the treatment of a treatment-resistant depressive episode without psychotic features. Her major complaints were depressive mood, anhedonia, fatigue, sleepiness, and adynamia. The last medication consisted of 10 mg/day of olanzapine and 45 mg/day of mirtazapine for 3 months in stable dose. Electroconvulsive therapy was considered but rejected by the patient. No significant findings were obtained by the physical examination. Electroencephalogram and electrocardiogram results showed no abnormalities, and the patient had no history of seizures and no history of substance-induced (e.g., antidepressants, psychostimulants) switch to mania.

In the first week after admission, mirtazapine was discontinued, olanzapine treatment was continued at 10 mg/day, and venlafaxine treatment was started at 75 mg/day, with a dose increase up to 300 mg/day within 4 weeks, followed by 7 weeks of treatment at that dose. After this unsuccessful 11-week trial of venlafaxine, 100 mg/day of modafinil was added. The modafinil dose was increased to 300 mg/day within 1 week. Her 17-item Hamilton Rating Scale for Depression<sup>7</sup> score dropped from 22 to 10 within 10 days after the point when the modafinil dose had reached 300 mg/day. Four days after she reached the target dose, her symptoms changed from anergia, fatigue, and lethargy to overactivity, insomnia without feeling tired during the day, and elevated mood with euphoria. No other side effects occurred. Because of the time course, venlafaxine is rather unlikely to be responsible for the manic switch. After 7 days of manic symptoms, modafinil was tapered out completely within 2 weeks, and olanzapine increased to 15 mg/day. Under this regimen, the patient became euthymic compared with her pre-morbid personality, which can be characterized as one that is a loner, not very talkative, rather impatient, and willful.

This is the first case report of a bipolar patient suffering from treatment-resistant depression with a manic switch during treatment with modafinil. According to the available data,<sup>2,8,9</sup> modafinil was regarded as rather safe concerning mood switches in treating depression. Unlike other psychostimulants, modafinil exhibits only weak affinity for the dopamine uptake carrier site and does not stimulate striatal dopamine release in rodents.<sup>10-12</sup> However, the fact that there are no reports about mood switches might be due to the limited number of bipolar

patients treated with modafinil and not necessarily due to its different mechanism of action. Therefore, when considering a treatment with modafinil for bipolar depression, caution should be taken regarding the possibility of manic switches, even in the presence of a mood stabilizer like olanzapine.

*The authors report no financial or other relationship relevant to the subject of this letter.*

#### REFERENCES

1. Fava M, Thase ME, De Battista C. A multicenter, placebo-controlled study of modafinil augmentation in partial responders to selective serotonin reuptake inhibitors with persistent fatigue and sleepiness. *J Clin Psychiatry* 2005;66:85-93
2. Menza MA, Kaufman KR, Castellanos A. Modafinil augmentation of antidepressant treatment in depression. *J Clin Psychiatry* 2000;61:378-381
3. De Battista C, Lembke A, Solvason HB, et al. A prospective trial of modafinil as an adjunctive treatment of major depression. *J Clin Psychopharmacol* 2004;24:87-90
4. Lundt L. Modafinil treatment in patients with seasonal affective disorder/winter depression: an open label pilot study. *J Affect Disord* 2004;81:173-178
5. Price CS, Taylor FB. A retrospective chart review of the effects of modafinil on depression as monotherapy and as adjunctive therapy. *Depress Anxiety* 2005;21:149-153
6. Vorspan F, Warot D, Consoli A, et al. Mania in a boy treated with modafinil for narcolepsy [letter]. *Am J Psychiatry* 2005;162:813-814
7. Hamilton M. A rating scale for depression. *J Neurol Neurosurg Psychiatry* 1960;23:56-62
8. Fernandes PP, Petty F. Modafinil for remitted bipolar depression with hypersomnia. *Ann Pharmacother* 2003;37:1807-1809
9. Bergian T. Modafinil treatment of excessive sedation associated with divalproex sodium. *Can J Psychiatry* 2004;49:72-75
10. Mignot E, Nishino S, Guilleminault C. Modafinil binds to the dopamine uptake carrier site with low affinity. *Sleep* 1994;17:436-437
11. de Serville JE, Boer C, Rambert F. Lack of presynaptic dopaminergic involvement in modafinil activity in anaesthetized mice: in vivo voltammetry studies. *Neuropharmacology* 1994;33:755-761
12. Lin JS, Roussel B, Akaoka H. Role of catecholamines in the modafinil and amphetamine induced wakefulness, a comparative pharmacological study in the cat. *Brain Res* 1992;591:319-326

Jürgen Wolf, M.D.

Ute Fiedler, M.D.

Ion Anghelescu, M.D.

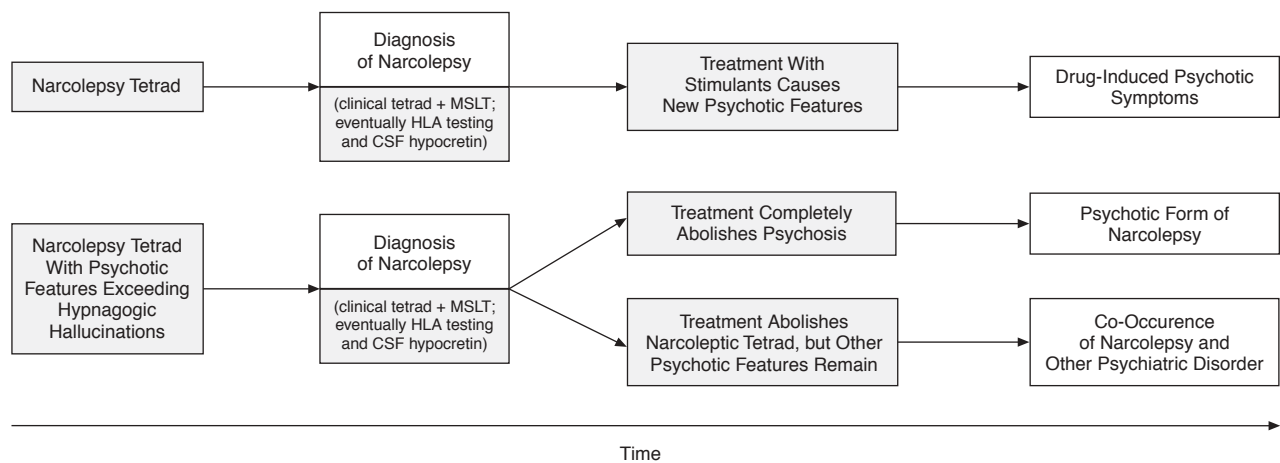
Natascha Schwertfeger, M.D.

Department of Psychiatry and Psychotherapy  
Charité-University Medicine-Campus Benjamin Franklin  
Berlin, Germany

### Diagnostic and Therapeutic Challenges in Narcolepsy-Related Psychosis

**Sir:** Psychosis related to narcolepsy may manifest in 3 ways: Firstly, narcolepsy may co-occur by chance with schizophrenia or other psychiatric disorders. Secondly, treatment of narcoleptic patients with central stimulants may lead to drug-induced psychotic symptoms.<sup>1</sup> Thirdly, some authors have argued for a "psychotic form of narcolepsy," in which the psychotic features exceed the common hypnagogic hallucinations.<sup>2,3</sup> Although cases with narcolepsy and simultaneous psychotic disorders have been sporadically described in the distant<sup>2</sup> and not so distant<sup>3</sup> literature, these patients are still frequently misdiagnosed

Figure 1. Flow Chart on the Differential Diagnosis of Narcolepsy-Related Psychosis



Abbreviations: CSF = cerebrospinal fluid, MSLT = multiple sleep latency test.

as having treatment-refractory schizophrenia, schizoaffective disorder, or bipolar depression. Thus, we provide a further case of narcolepsy-related psychosis to stress the necessity of a thorough differential diagnosis, and we discuss pharmacologic treatment with special emphasis on the dopamine and hypocretin systems.

**Case report.** A 38-year-old woman was referred from her psychiatrist to a neurologic outpatient clinic in June 2005 with a working diagnosis of partial complex epilepsy. From the age of 17 years she had experienced hypnagogic visual, auditory, and tactile hallucinations, which included the perception of men or animals sitting on her chest, taking her breath, and pulling on her legs and arms. During these episodes, she was aware that the creatures did not exist in reality, but being unable to move or shout she felt herself helplessly exposed. Similar episodes of sleep paralysis during day or night could also occur without hallucinations. Cataplexy could be induced by sudden positive or negative emotions. Although her night sleep was increasingly disturbed by frequent awakenings, she had suffered from excessive sleepiness since her teenage years and sleep attacks could occur in monotonous situations.

During the last 20 years, our patient had experienced recurrent depressions and anxiety. Moreover, she exhibited persecutory delusions with increased suspiciousness and ideas of reference. She felt that radio and television commented on her activities and was sometimes afraid that her food might have been poisoned. She described zonaesthesias such as the feeling of her heart opening itself. Our patient had been in psychiatric treatment for several years and had been diagnosed both with recurrent psychotic depression and treatment-refractory schizophrenia-like disorder. She had tried the atypical neuroleptics risperidone, olanzapine, and ziprasidone, which all had been stopped due to side effects. On referral, her medication consisted of dosulepin (tricyclic antidepressant), quetiapine (atypical neuroleptic), and a benzodiazepine at bedtime. Findings of an examination, including a full neurologic assessment, were normal, as were those of electroencephalogram and a computed tomography scan of the brain. The initial working diagnosis of complex partial epilepsy was abandoned.

Instead, a working diagnosis of narcolepsy was made and a multiple sleep latency test (MSLT) and polysomnography were

ordered. MSLT results were consistent with narcolepsy with an overall sleep latency of 3 minutes 45 seconds and an average rapid eye movement latency of 1 minute in 3 of 3 naps. Given these results and the classic tetrad of cataplexy, hypnagogic hallucinations, sleep paralysis, and excessive daytime sleepiness, we diagnosed narcolepsy and decided to renounce HLA testing and measurement of hypocretin in cerebrospinal fluid. Treatment with methylphenidate 10 mg thrice daily was initiated, which reduced hypnagogic hallucinations and excessive daytime sleepiness significantly. Dosulepin was continued to treat cataplexy and depression, and quetiapine was continued to treat delusions. However, our patient still suffered from moderate episodes of depression, mild paranoid delusions, and zonaesthesias, which clinically was consistent with a coexisting schizoaffective disorder according to ICD-10 criteria.

Narcolepsy is related to a nearly total loss of the recently discovered hypocretin neurons,<sup>4</sup> which project from the hypothalamus to the locus ceruleus, raphe nuclei, substantia nigra, and tuberomammillary nucleus.<sup>5</sup> Hypocretin thereby increases, under normal conditions, the release of wake-inducing monoamines leading to activation of the reticular activating system and other brain areas. Cataplexy is believed to be associated with decreased action of norepinephrine and serotonin and is consequently treated with tricyclic antidepressants. Agents such as methylphenidate increase dopaminergic activity and thus relieve excessive sleepiness.

Psychosis related to narcolepsy represents, therefore, a therapeutic dilemma. While central stimulants lead to hyperdopaminergia and thus may evoke drug-induced psychotic symptoms, neuroleptics used to treat psychosis block dopamine and have sedative effects. Methylphenidate-associated psychotic symptoms appear to be dose-related, and low doses probably seldom cause psychosis in narcoleptic patients<sup>1</sup> relative to the incidence seen with high doses.<sup>6</sup> However, in some patients, methylphenidate even completely stops not only hypnagogic hallucinations but also additional psychotic features. This is why a "core psychotic form of narcolepsy" has been suggested by some authors.<sup>2,3</sup> Since our patient had persecutory delusions, zonaesthesias, and mood disturbances before and after narcolepsy was treated, she was diagnosed with both narcolepsy and schizoaffective disorder (Figure 1).

In cases where the clinician believes that methylphenidate evokes or worsens psychotic symptoms, sodium gamma-hydroxybutyrate, which is still unapproved in most European countries, and modafinil are alternatives. The nonamphetamine stimulant modafinil possibly acts on polysynaptic circuits of dopaminergic-adrenergic and GABAergic-glutamatergic systems, which could lead to activation of those few hypocretin neurons that survive in narcolepsy. However, according to a recent report of a patient with schizophrenia, modafinil, like other psychostimulants, might exacerbate psychosis.<sup>7</sup>

Our patient had been treated with 4 atypical neuroleptics and experienced relatively good control of psychotic symptoms with quetiapine, which is why we decided not to perform any further medication trials. At least from a theoretical point of view, the new antipsychotic aripiprazole might be a good choice for treatment of patients with narcolepsy and psychosis. Since aripiprazole is a dopamine stabilizer antagonizing both hyperdopaminergia and hypodopaminergia,<sup>8</sup> and is not a primary dopamine blocker as are all other neuroleptics, it may have the potential to solve the dopamine dilemma of narcolepsy-related psychosis. To our knowledge, there are no reports in the literature of aripiprazole used in such patients.

*Drs. Kondziella and Arlien-Soborg report no financial affiliations or other relationships relevant to the subject of this letter.*

#### REFERENCES

1. Auger RR, Goodman SH, Silber M. Risks of high-dose stimulants in the treatment of disorders of excessive somnolence: a case-control study. *Sleep* 2005;28:667–672
2. Douglass A, Hays P, Pazderka F, et al. Florid refractory schizophrenias that turn out to be treatable variants of HLA-associated narcolepsy. *J Nerv Ment Dis* 1991;179:12–17
3. Kishi Y, Konishi S, Koizumi S. Schizophrenia and narcolepsy: a review with a case report. *Psychiatry Clin Neurosci* 2004;58:117–124
4. Thannickal TC, Moore RY, Nienhuis R, et al. Reduced number of hypocretin neurons in human narcolepsy. *Neuron* 2000;27:469–474
5. Peyron C, Tighe DK, van den Pol AN, et al. Neurons containing hypocretin (orexin) project to multiple neuronal systems. *J Neurosci* 1998;18:9996–10015
6. Pawluk L, Hurwitz T, Schluter JI, et al. Psychiatric morbidity in narcoleptics on chronic high dose methylphenidate therapy. *J Nerv Ment Dis* 1995;183:834–841
7. Narendran R, Young CM, Valenti AM, et al. Is psychosis exacerbated by modafinil? *Arch Gen Psychiatry* 2002;59:292–293
8. Carlsson M, Carlsson A, Nilsson M. Schizophrenia: from dopamine to glutamate and back. *Curr Med Chem* 2004;11:267–277

**Daniel Kondziella, M.D., Ph.D.**  
**Peter Arlien-Soborg, M.D., Ph.D.**

Department of Neurology  
Rigshospitalet, Copenhagen University Hospital  
Copenhagen, Denmark

### Beneficial Effects of Prazosin for Visual Hallucinations Associated With Chronic Cocaine Abuse

**Sir:** Visual hallucinations are a common and often refractory psychotic symptom associated with chronic psychostimulant abuse.<sup>1</sup> We report the apparent effectiveness of the  $\alpha_1$ -adrenergic antagonist prazosin for antipsychotic drug-resistant visual hallucinations in a patient with chronic abuse of crack cocaine. Because the patient's visual hallucinations and associ-

ated anxiety resembled trauma nightmares that are responsive to prazosin in posttraumatic stress disorder (PTSD),<sup>2</sup> a trial of prazosin was undertaken.

**Case report.** Mr. A, a 51-year-old man, was admitted to the hospital in 2004 because he heard voices commanding him to burn down his home to rid it of visually hallucinated insects. Although he had heavily used crack cocaine for 20 years, he had experienced psychotic symptoms only during the previous year. Based on partial response to a previous, outpatient trial of olanzapine, initial treatment was olanzapine 25 mg/day. A week later, quetiapine, 200 mg/day, was added in an attempt to simultaneously augment the antipsychotic effects of olanzapine and to aid in sleep. His auditory hallucinations gradually faded to unintelligible whispers, apparently responding to the predominantly dopaminergic effects of the atypical antipsychotics.

However, frightening visual hallucinations persisted, severely compromising his ability to eat, sleep, and participate in treatment. The patient's daytime visual hallucinations included menacing creatures and insects crawling in his food. He was not able to distinguish nighttime hallucinations, including vivid images of insects, lizards, and monsters, from nightmares. Although quetiapine does block  $\alpha_1$ -adrenergic receptors and has shown some benefit for PTSD, the nightmarish quality of the patient's visual disturbances prompted a trial of the potent  $\alpha_1$ -antagonist prazosin. Thus, quetiapine was discontinued after 4 weeks and prazosin 2 mg q.h.s. was begun. The patient reported an immediate decrease in visual hallucinations after the initiation of prazosin. After prazosin was increased to 2 mg b.i.d. 2 weeks later, residual visual hallucinations disappeared entirely.

Although this improvement in visual hallucinations may have been due to the combined effects of olanzapine and prazosin, it is more likely that this particular effect reflected the unique actions of prazosin.  $\alpha_1$ -Adrenergic receptors may be involved in the pathophysiology of visual hallucinations associated with psychostimulant abuse. In animal models, recent studies<sup>3,4</sup> demonstrate  $\alpha_1$ -adrenergic involvement in brain adaptations to psychostimulants. Dopaminergic receptors and dopamine neuron burst firing are modulated via norepinephrine stimulation of  $\alpha_1$ -adrenergic receptors, and these effects are blocked by prazosin.<sup>3,4</sup> In addition, behavioral sensitization induced by repeated injections of psychostimulants is blocked by prazosin.<sup>5</sup> Taken together, these clinical observations and pre-clinical studies support further investigation of prazosin in the treatment of psychostimulant-induced visual hallucinations and other disorders characterized by visual hallucinations.

*Drs. Tapp, Kennedy, Peskind, and Raskind report no financial or other relationship relevant to the subject of this letter.*

*The views expressed in this letter are those of the authors and do not necessarily represent the views of VA Puget Sound Health Care System.*

#### REFERENCES

1. Caton CL, Drake RE, Hasin DS, et al. Differences between early-phase primary psychotic disorders with concurrent substance use and substance-induced psychoses. *Arch Gen Psychiatry* 2005;62:137–145
2. Raskind MA, Peskind ER, Kanter ED, et al. Reduction of nightmares and other PTSD symptoms in combat veterans by prazosin: a placebo-controlled study. *Am J Psychiatry* 2003;160:371–373
3. Shi WX, Pun CL, Zhang XX, et al. Dual effects of D-amphetamine on dopamine neurons mediated by dopamine and nondopamine receptors. *J Neurosci* 2000;20:3504–3511
4. Paladini CA, Mitchell JM, Williams JT, et al. Cocaine self-administration selectively decreases noradrenergic regulation of metabotropic glutamate receptor-mediated inhibition in dopamine neurons. *J Neurosci* 2004;24:5209–5215

5. Drouin C, Blanc G, Villegier AS, et al. Critical role of alpha1-adrenergic receptors in acute and sensitized locomotor effects of D-amphetamine, cocaine, and GBR 12783: influence of preexposure conditions and pharmacological characteristics. *Synapse* 2002;43:51–61

**Andre M. Tapp, M.D.**  
**Annette Kennedy, Psy.D.**  
**Elaine R. Peskind, M.D.**  
**Murray A. Raskind, M.D.**

VA Puget Sound Health Care System  
 Seattle and Tacoma, Washington

### Fluoxetine-Mirtazapine Interaction May Induce Restless Legs Syndrome: Report of 3 Cases From a Clinical Trial

**Sir:** Restless legs syndrome (RLS) is a sleep disorder that may be induced or worsened by several antidepressants,<sup>1</sup> a fact that provides us with working hypotheses on the neurochemical basis of RLS. Mirtazapine is an effective antidepressant with 5-HT<sub>2A</sub>, 5-HT<sub>3</sub>, and norepinephrine  $\alpha_2$ -antagonist properties, which may induce RLS according to previous case reports.<sup>2–4</sup>

**Case report.** We report 3 cases of patients who developed RLS after taking mirtazapine and fluoxetine as part of an ongoing clinical trial (begun in May 2004). Patients with DSM-IV major depressive disorder and insomnia received 20 mg/day of fluoxetine for 2 weeks, had a polysomnography (PSG) recording done (baseline), and were then randomly assigned to receive, in addition to fluoxetine, 15 mg/day of mirtazapine (N = 5) or 1 to 2 mg/day of lorazepam (N = 6) nightly for 2 weeks, after which a final PSG was obtained (endpoint).

At baseline, none of the patients in either group reported symptoms of RLS upon direct interrogation. At endpoint, in the group treated with fluoxetine and mirtazapine only, we had the following results: 2 women aged 63 and 50 years and 1 man aged 41 years, who were otherwise healthy adults as established by medical history, physical examination, and routine laboratory studies, and who had no personal or family history of RLS, spontaneously reported symptoms characteristic of RLS and requested to discontinue medication. The reported symptoms were bothersome paresthesias and jerks in both lower extremities, with exacerbation during the night and characteristic relief upon movement; the male patient also had involvement of the arms during the day severe enough to impede labor activities requiring fine manufactured work.

Baseline PSG revealed in these 3 patients, but not in the other patients, an established periodic limb movement disorder (PLMD; 30.2 and 41.3 mean limb movements per hour of sleep for the women and 67.6 for the man). Endpoint PSG revealed a slight exacerbation of PLMD in the women (mean per hour of 32.0 and 56.3, respectively) but not in the man (mean per hour of 61.6). Treatment with mirtazapine was discontinued after endpoint PSG, and symptoms ceased completely after 2 days.

The present case series supports previous reports of RLS induced by mirtazapine and also suggests fluoxetine could facilitate this outcome, possibly through induction of PLMD. In contrast to our findings, 1 retrospective study of 200 consecutive cases of depressed patients with insomnia<sup>5</sup> failed to find an association between RLS and antidepressant use. However, we believe that finding could be explained by the relatively low net

number of patients taking the same medication so that RLS, an uncommon side effect, may have been missed. On the other hand, however, the contrast in findings between that study and ours helps point out that combining drugs with the same potential side effect may switch that side effect's presentation from rare to surprisingly common, as exemplified in our case series (3 affected patients out of 5). Hence, we suggest that although combining fluoxetine and mirtazapine may be helpful in depressed patients with marked insomnia, surveillance should constantly be made for the development of RLS when using this combination.

*The authors report no financial affiliations or other relationships relevant to the subject of this letter.*

#### REFERENCES

- Picchiotti D, Winkelman JW. Restless legs syndrome, periodic limb movements in sleep, and depression. *Sleep* 2005;28:891–898
- Bonin B, Vandel P, Kantelip JP. Mirtazapine and restless leg syndrome: a case report. *Therapie* 2000;55:655–656
- Agargun MY, Kara H, Ozbek H, et al. Restless legs syndrome induced by mirtazapine [letter]. *J Clin Psychiatry* 2002;63:1179
- Bahk WM, Pae CU, Chae JH, et al. Mirtazapine may have the propensity for developing a restless legs syndrome? a case report. *Psychiatry Clin Neurosci* 2002;56:209–210
- Brown LK, Dedrick DL, Doggett JW, et al. Antidepressant medication use and restless legs syndrome in patients presenting with insomnia. *Sleep Med* 2005;6:443–450

**Keiko A. Prospero-Garcia, M.D.**  
**Antonio Torres-Ruiz, M.D.**

**Jesus Ramirez-Bermudez, M.D.**

Department of Neuropsychiatry  
 National Institute of Neurology and Neurosurgery  
 Mexico City, Mexico

**Javier Velazquez-Moctezuma, M.D., Ph.D.**

**Yoaly Arana-Lechuga, B.A.**

**Guadalupe Teran-Perez, B.A.**

Sleep Disorders Clinic  
 Universidad Autónoma Metropolitana-Iztapalapa  
 Mexico City, Mexico

### Tactile Hallucinations Associated With Therapeutic Doses of Bupropion in 2 Patients

**Sir:** Formication is a rare complication of bupropion overdose.<sup>1</sup> We report 2 cases of formication associated with therapeutic doses of bupropion.

**Case 1.** Ms. A was a 39-year-old African American woman with DSM-IV-TR posttraumatic stress disorder and major depression and cocaine dependence in full remission for 10 months. Her medical problems included hypertension, hypercholesterolemia, back pain, constipation, gastroesophageal reflux disease, and recent galactorrhea of unknown etiology, following a work-up that included normal serum levels of prolactin, follicle-stimulating hormone, luteinizing hormone, and estradiol. She was taking buspirone, felodipine, fluoxetine, hydrochlorothiazide, omeprazole, simvastatin, sulindac, and psyllium powder.

We added bupropion SR, titrated to 200 mg twice daily during 2 to 3 weeks, to augment fluoxetine. Within 3 weeks, Ms. A complained of “bugs crawling” over her skin, noting she had had similar experiences when using cocaine. There was no evi-



dence of cocaine use; Ms. A was living in a residential drug treatment program that monitored her closely, and she had no aberrant behavior. Urine drug testing was not available at the time. She denied other side effects or psychotic symptoms. Her symptoms abated after her total daily dose of bupropion SR was reduced to 300 mg. Subsequent laboratory studies were normal. She remained free of tactile hallucinations.

**Case 2.** Ms. B was a 40-year-old white woman with recurrent DSM-IV-TR major depression. Her medical problems included gastroesophageal reflux disease, treatment-refractory migraine headaches, obstructive sleep apnea, and hypothyroidism. She was taking levothyroxine, loratadine, montelukast, ranitidine, riboflavin, Fioricet as needed for migraines, gabapentin or trazodone as needed for insomnia, and ibuprofen.

We started bupropion SR and titrated the dosage to 200 mg twice daily during 3 months, and her depression remitted. Eleven months into treatment, Ms. B admitted that soon after increasing her dosage of bupropion to 200 mg twice daily, she developed continuous mild tactile hallucinations, like "a feeling of bugs crawling on my skin." She delayed mentioning these mildly distressing symptoms, thinking they would go away and wanting to continue bupropion. She denied other side effects or psychotic symptoms. No other medications had been introduced during this time. Her tactile hallucinations ceased after her total daily dose of bupropion SR was reduced to 300 mg.

Several experimental models suggest bupropion potentiates dopaminergic neurotransmission.<sup>2-6</sup> Clinically, the most limiting side effects are stimulant-like, including agitation, tremor, or insomnia. Tactile hallucinations described as a "bug crawling" feeling on the skin are common with stimulant toxicity ("cocaine bugs"), presumably due to dopaminergic excess.<sup>7</sup> This is the first case report of tactile hallucinations associated with therapeutic doses of bupropion.

In one review of reports of intentional bupropion overdose, about 5% of patients presented with hallucinations, often described as "bugs crawling over my skin." Hallucinations frequently preceded seizures, which were associated with ingestions of between 600 mg to 18 g of bupropion.<sup>8</sup> Visual and auditory hallucinations may emerge after initiation of bupropion in patients with unipolar or bipolar depression.<sup>9-11</sup> Dose reduction or discontinuation is associated with cessation of such symptoms, although sometimes antipsychotic medication is also used. Acute auditory hallucinations and paranoid delusions emerged in a patient receiving bupropion only for nicotine addiction.<sup>12</sup>

Our patients did not have psychotic or bipolar disorders. They neither experienced other stimulant side effects nor required antipsychotic treatment. The dose titration was slow in case 2 and more rapid in case 1. Our cases suggest that dopaminergic effects of bupropion may be significant in vivo at typical doses and under typical dose titration schedules and can cause tactile hallucinations in the absence of other stimulant side effects or psychotic symptoms.

*The authors report no financial or other affiliation relevant to the subject of this letter.*

#### REFERENCES

1. Shepherd G, Velez LI, Keyes DC. Intentional bupropion overdoses. *J Emerg Med* 2004;27:147-151
2. Cooper BR, Hester TJ, Maxwell RA. Behavioral and biochemical effects of the antidepressant bupropion (Wellbutrin): evidence for selective blockade of dopamine uptake in vivo. *J Pharmacol Exp Ther* 1980;215:127-134
3. Hudziak J, Rettew D. Bupropion. In: Schatzberg A, Nemeroff C, eds.

Textbook of Psychopharmacology. Washington, DC: American Psychiatric Publishing; 2004:327-341

4. Horst WD, Preskorn SH. Mechanisms of action and clinical characteristics of three atypical antidepressants: venlafaxine, nefazodone, bupropion. *J Affect Disord* 1998;51:237-254
5. Petrie EC, Veith RC, Szot P. Bupropion and desipramine increase dopamine transporter mRNA expression in the ventral tegmental area/substantia nigra of rat brain. *Prog Neuropsychopharmacol Biol Psychiatry* 1998;22:845-856
6. Zarrindast MR, Hodjati MR, Pejhan A, et al. Bupropion induces sniffing: a possible dopaminergic mechanism. *Eur Neuropsychopharmacol* 1996;6:299-303
7. Mitchell J, Vierkant AD. Delusions and hallucinations of cocaine abusers and paranoid schizophrenics: a comparative study. *J Psychol* 1991;125:301-310
8. Shepherd G, Velez LI, Keyes DC. Intentional bupropion overdoses. *J Emerg Med* 2004;27:147-151
9. Ames D, Wirshing WC, Szuba MP. Organic mental disorders associated with bupropion in three patients. *J Clin Psychiatry* 1992;53:53-55
10. Becker RE, Dufresne RL. Perceptual changes with bupropion, a novel antidepressant. *Am J Psychiatry* 1982;139:1200-1201
11. Golden RN, James SP, Sherer MA, et al. Psychoses associated with bupropion treatment. *Am J Psychiatry* 1985;142:1459-1462
12. Neumann M, Livak V, Paul HW, et al. Acute psychosis after administration of bupropion hydrochloride (Zyban). *Pharmacopsychiatry* 2002;35:247-248

**Anthony Charuvastra, M.D.**  
**Deborah Yaeger, M.D.**

Department of Psychiatry and Biobehavioral Sciences  
University of California, Los Angeles  
Los Angeles, California

#### Immediate Switching From Moclobemide to Duloxetine May Induce Serotonin Syndrome

**Sir:** Serotonin syndrome is a drug reaction resulting from an excessive serotonergic agonism of both central nervous system receptors and peripheral serotonergic receptors.<sup>1</sup> It is clinically characterized by autonomic hyperactivity, neuromuscular abnormalities, and mental status changes.<sup>1,2</sup> Drugs associated with serotonin syndrome include antidepressants taken independently or in combination with other antidepressants or with other drugs (e.g., analgesics, antibiotics, drugs of abuse) in therapeutic doses.<sup>1,2</sup> Monoamine oxidase inhibitors (MAOIs), especially when they are used in combination with selective serotonin reuptake inhibitors (SSRIs), have been associated with severe forms of serotonin syndrome.<sup>3</sup> Here I describe the case of a patient who developed a serotonin syndrome after her treatment was switched from moclobemide, a reversible inhibitor of monoamine oxidase type A, to duloxetine, a serotonin-norepinephrine reuptake inhibitor (SNRI).

**Case report.** Ms. A, a 46-year-old single woman, had a history of DSM-IV major depressive disorder since she was 38 years old. In 2001, she began a 4-year treatment period with moclobemide (300 mg/day). During the first year, the treatment also included clonazepam (0.5 mg/day), but then this drug was replaced with amitriptyline (6.25 mg/day) because of persistent mild sleep problems. In the last 2 years she experienced 2 recurrences of depressive symptoms. While the first recurrence improved by increasing her moclobemide dose (to 450 mg/day), the second recurrence did not show any response to an additional increase (to 600 mg/day), which she took for 4 weeks, so I decided to discontinue her moclobemide treatment and began

treating her with duloxetine (60 mg/day). She commenced the duloxetine treatment the morning after a nocturnal dose of moclobemide. One hour after duloxetine ingestion, the patient began to feel intense restlessness, generalized tremor, dizziness, nausea, headache, and tics-like facial movements. Although these symptoms were more intense during the morning and diminished through the day, they did not disappear completely, and insomnia reappeared. On the second day of duloxetine treatment, she also experienced a blood pressure increase (to 130/90 mm Hg). Other symptoms, such as fever, diarrhea, dyspnea, and sweating, were absent. She called me after 4 days of treatment to let me know about these manifestations, so I instructed her to attend an emergency department and to discontinue duloxetine. While she did not attend any emergency department, she called my office 2 days after duloxetine withdrawal, and all her symptoms had completely disappeared. Treatment with moclobemide was reinstated after a 1-week washout period.

Serotonin syndrome is an increasing problem given the current prescription practices in the treatment of depression, which favor the use of SSRIs and SNRIs over tricyclic antidepressants. A particularly crucial area of concern is the management of treatment-resistant depression, for which the most common pharmacologic approach has been switching from an ineffective drug to another antidepressant. However, as this case clearly shows, such a strategy is not risk-free. Although moclobemide is considered safer than older nonselective MAOIs because it does not produce the so-called "tyramine reaction,"<sup>4</sup> a growing association with serotonin syndrome has been found recently.<sup>2</sup> In the case I describe here, it may be argued that serotonin toxicity symptoms derive from duloxetine ingestion. However, Graudins et al.<sup>3</sup> have described a similar case in which a patient presented such symptoms induced by a moclobemide-paroxetine interaction. Therefore, even though moclobemide has a short plasma elimination half-life, the switch to another antidepressant should be made with caution. Likewise, dulox-

etine is an antidepressant that has become available only recently, and, as far as I know, this is the first report of duloxetine-associated serotonin syndrome. Although the patient did not meet Sternbach<sup>1</sup> criteria for serotonin syndrome, her symptoms, which could be considered minor side effects, seem to represent a mild form of serotonin syndrome that would probably be overlooked if strict criteria were used.<sup>2</sup>

Even the simpler Hunter criteria<sup>5</sup> are difficult to apply in this case, given the lack of a physical examination. However, all the symptoms that the patient subjectively reported fall into the spectrum of serotonin toxicity, which ranges from mild symptoms or few symptoms (e.g., tremor and diarrhea) to life-threatening manifestations such as hyperthermia, delirium, and hypertonicity.<sup>2</sup> Therefore, clinicians should be aware of serotonin syndrome symptoms so that they are able to inform patients about them and to opportunistically intervene when toxicity occurs.

*Dr. Jimenez-Genchi has received support from and is an employee of the National Institute of Psychiatry Ramon de la Fuente of Mexico.*

#### REFERENCES

1. Sternbach H. The serotonin syndrome. *Am J Psychiatry* 1991;148:705-813
2. Boyer EW, Shanon M. The serotonin syndrome. *N Engl J Med* 2005;352:1112-1120
3. Graudins A, Stearman A, Chan B. Treatment of the serotonin syndrome with cyproheptadine. *J Emerg Med* 1998;16:615-619
4. Bonnet U. Moclobemide: therapeutic and clinical studies. *CNS Drug Rev* 2003;9:97-140
5. Dunkley EJC, Isbister GK, Sibbritt D, et al. The Hunter Serotonin Toxicity Criteria: simple and accurate diagnostic decision rules for serotonin toxicity. *QJM* 2003;96:635-642

**Alejandro Jimenez-Genchi, M.D.**

Clinical Services  
National Institute of Psychiatry Ramon de la Fuente  
Mexico City, Mexico