

### Gabapentin Abuse, and Delirium Tremens Upon Gabapentin Withdrawal

**Sir:** Gabapentin is one of a new generation of antiepileptic drugs widely used in recent years for a variety of indications, including epilepsy, neuropathic pain, migraine, and bipolar disorder. Although gabapentin is structurally analogous to  $\gamma$ -aminobutyric acid (GABA), it does not appear to affect GABA uptake or the GABA<sub>A</sub> or GABA<sub>B</sub> receptors. The basis of its anticonvulsant efficacy is unclear, but it may include inhibition of certain voltage-activated calcium channels.<sup>1</sup> Gabapentin increases brain GABA concentration and turnover.<sup>2</sup> Given this effect, it is perhaps not surprising that several studies have shown that gabapentin decreases alcohol withdrawal symptoms and may decrease cravings for alcohol in alcohol-dependent individuals.<sup>3,4</sup>

While gabapentin has low abuse potential, abuse has been described in cocaine-dependent individuals. One report describes the abuse of gabapentin by snorting in 5 cocaine-dependent prison inmates.<sup>5</sup> Another case report describes a patient who reported reduced cocaine craving through the use of 600 to 1500 mg/day of gabapentin, prescribed for another individual.<sup>6</sup>

A small number of reports have described withdrawal symptoms after discontinuation of gabapentin. Norton<sup>7</sup> described 3 cases of withdrawal in patients taking 4800, 3600, and 2400 mg/day: the first 2 developed elevated vital signs, confusion, agitation, and diaphoresis over a 2- to 3-day period, and the last developed irritability, headache, and diaphoresis over a 2-day period. A case similar to this last is also described by Drabkin and Calhoun.<sup>8</sup> Another patient taking 8000 mg/day developed status epilepticus 3 days after discontinuation of drug.<sup>9</sup> Yet another patient developed catatonia after gabapentin discontinuation.<sup>10</sup> This is notable because catatonia has been described after withdrawal from benzodiazepines, which also increase GABA transmission. Here we describe 2 patients who used larger doses of gabapentin than prescribed and who then developed a withdrawal syndrome similar to delirium tremens upon discontinuation of the drug.

**Case 1.** Mr. A, a 33-year-old man, had a history of hepatitis C. He had a history of alcohol and other drug dependence, including a history of delirium tremens with alcohol withdrawal, but he had been using only cannabis, according to multiple reliable sources, for at least 6 months prior to the admission reported here. However, for at least that time he had been taking 3600 mg/day of gabapentin, twice his prescribed dose, because he felt the medication reduced his cravings for alcohol and made him feel calmer. Office staff routinely authorized early refills. He was also prescribed paroxetine and quetiapine. In 2005, he ran out of gabapentin and abruptly stopped the medication after office staff were instructed not to permit early refills. On the third day off gabapentin, he was found by a roommate to be confused and diaphoretic and was brought to the hospital. He was disoriented, agitated, tachycardic, hyper-reflexic, and tremulous, and he was admitted to the hospital. He was treated with lorazepam (to a total of 6 mg) and haloperidol (to a total of 10 mg) on hospital day 2 without benefit. Gabapentin was resumed on hospital day 3 at 600 mg every 8 hours, and his symptoms resolved fully over the next 2 days. No oculomotor palsy, pendular nystagmus, or ataxia was seen. No other etiology for this mental status change was found. On admission, urine toxicology screen was positive only for can-

nabis, and blood alcohol screen was negative. Mean corpuscular volume was within normal limits.

**Case 2.** Mr. B, a 63-year-old man, had a medical history significant for severe chronic back pain and multiple back surgeries. At the time of presentation, he was being prescribed and was taking oxycodone and gabapentin. He had a history of significant alcohol use in the past but had used none in over a decade. In 2005, he presented to the emergency department after several days of fatigue, increasing sedation, and confusion. He was found to have taken an average estimated daily dose of 4900 mg of gabapentin for the last 11 days, although it was prescribed at 1800 mg/day. Investigation determined that he had been using similarly high doses of gabapentin for many months. He was treated with a total lorazepam dose of 4 mg on each of the first and second days in hospital for periods of agitation. Gabapentin was stopped. On the third day in hospital, he was noted to be confused and hallucinating. He rapidly became tachycardic to 120 b.p.m., febrile to 100.5°F, diaphoretic, tremulous, and agitated. He was treated with 26 mg of lorazepam on hospital day 4 and with 22 mg of lorazepam on hospital day 5, with limited improvement. Gabapentin was resumed at 300 mg every 6 hours on hospital day 6. He quickly became more lucid, and his vital signs stabilized. As in the first case, the examination findings were not consistent with a Wernicke syndrome, and work-up did not disclose any other etiology for his change of mental status. The patient made a full recovery.

Several classes of drugs that modulate GABAergic neurotransmission, including ethanol, benzodiazepines, and barbiturates, have abuse potential. Gabapentin abuse has previously been described in individuals with a history of cocaine dependence. Our observations suggest that gabapentin abuse can also occur in individuals with a history of heavy alcohol use. To our knowledge, gabapentin abuse has only been described in individuals with a history of exposure to addictive substances.

Cessation of ethanol, benzodiazepines, or barbiturates can produce a withdrawal delirium. Both cases described here demonstrated all of the cardinal features of delirium tremens, or alcohol withdrawal delirium, as defined by the DSM-IV-TR.<sup>11</sup> Both patients received lorazepam in the hospital, with possible benefit in 1 case. Whether benzodiazepines are useful in the treatment of gabapentin withdrawal is unclear from these 2 narratives. Both patients, as well as the 2 other reported cases of confusion during gabapentin withdrawal, were using doses of 3600 mg/day or higher. It may be that severe withdrawal reactions will be observed only with relatively high daily doses of this drug. The combination of abuse potential and a physiologically significant withdrawal syndrome emphasizes that gabapentin may share some of the undesirable characteristics of other pharmacologic agents that modulate GABAergic neurotransmission.

*The authors report no financial affiliation or other relationships that can be considered a conflict of interest relevant to the subject of this letter.*

#### REFERENCES

1. Rogawski MA, Löscher W. The neurobiology of antiepileptic drugs. *Nat Rev Neurosci* 2004;5:553-564
2. Petroff OAC, Hyder F, Rothman DL, et al. Effects of gabapentin on brain GABA, homocarnosine, and pyrrolidinone in epilepsy. *Epilepsia* 2000;41:675-680
3. Johnson BA, Swift RM, Addolorato G, et al. Safety and efficacy of GABAergic medications for treating alcoholism.

- Alcohol Clin Exp Res 2005;29:248–254
4. Chatterjee CR, Ringold AL. A case report of reduction in alcohol craving and protection against alcohol withdrawal by gabapentin [letter]. *J Clin Psychiatry* 1999;60:617
  5. Reccoppa L, Malcolm R, Ware M. Gabapentin abuse in inmates with prior history of cocaine dependence. *Am J Addict* 2004;13:321–323
  6. Markowitz JS, Finkbine R, Myrick H, et al. Gabapentin abuse in a cocaine user: implications for treatment? *J Clin Psychopharmacol* 1997;17:423–424
  7. Norton JW. Gabapentin withdrawal syndrome. *Clin Neuropharmacol* 2001;24:245–246
  8. Drabkin R, Calhoun L. Anorgasmia and withdrawal syndrome in a woman taking gabapentin. *Can J Psychiatry* 2003;48:125–126
  9. Barreto F, Green J, Howland MA, et al. Gabapentin withdrawal presenting as status epilepticus. *J Toxicol Clin Toxicol* 2002;40:925–928
  10. Rosebush PI, MacQueen GM, Mazurek MF. Catatonia following gabapentin withdrawal. *J Clin Psychopharmacol* 1999;19:188–189
  11. American Psychiatric Association. *Diagnostic and Statistical Manual of Mental Disorders, Fourth Edition, Text Revision*. Washington, DC: American Psychiatric Association; 2000

**Christopher Pittenger, M.D., Ph.D.**  
**Paul H. Desan, M.D., Ph.D.**

Department of Psychiatry  
 Yale New Haven Hospital  
 New Haven, Connecticut

### Chronic Leukocytosis Associated With Clozapine: A Case Series

**Sir:** The potential for clozapine, a dibenzodiazepine derivative, to cause leukopenia/agranulocytosis is well-known; however, leukocytosis associated with clozapine has been reported infrequently, particularly in the U.S. literature. Persistent clozapine-associated leukocytosis without fever or other complications is rarely reported.<sup>1</sup> Leukocytosis, defined as a white blood cell (WBC) count greater than 11,000/mm<sup>3</sup> ( $11 \times 10^9/L$ ), is frequently found in the course of routine laboratory testing. An elevated WBC count reflects the typical response of bone marrow to infectious or inflammatory processes.<sup>2</sup>

Leukocytosis can occur as a result of physical and emotional stress, such as overexertion, seizures, anxiety, anesthesia, and epinephrine administration.<sup>3,4</sup> However, this process is a transient one that is not related to marrow production or the release of immature blood cells. Other causes of leukocytosis that may be persistent include medications, splenectomy, hemolytic anemia, and malignancy. Medications that have been reported to cause leukocytosis include corticosteroids, lithium, and  $\beta$  agonists.<sup>5</sup> High smoking rates are associated with increases in total and differential WBC counts.<sup>6</sup>

The incidence of hematologic adverse effects in clinical trials of clozapine was as follows: leukopenia/decreased WBC/neutropenia = 3%, agranulocytosis = 1%, and eosinophilia = 1%. Less frequent (< 1%) hematologic adverse effects in pre-marketing trials included anemia and leukocytosis.<sup>7</sup> Post-marketing clinical experience revealed reports of elevated hemoglobin/hematocrit, increased erythrocytic sedimentation rate, thrombocytosis, and thrombocytopenia.<sup>7</sup>

We report cases of chronic leukocytosis in afebrile patients in this case series from the clinical experience of the first author (S.M.) in nursing homes.

#### Method

All cases of chronic leukocytosis associated with clozapine use from the clinical practice of the first author (S.M.) during a

5-year period, for which other etiologic factors have been excluded, were analyzed retrospectively. All cases of transient and intermittent leukocytosis were excluded. The study was approved by the Institutional Review Board of St. John's Episcopal Hospital, Far Rockaway, N.Y. Demographic factors like age, sex, race, concurrent medication—psychotropics and nonpsychotropics—concurrent medical diagnosis, dose of clozapine and duration of treatment, psychiatric diagnosis, and at least 3 WBC counts (total and differential) during a 2- to 5-year period were reviewed. Case histories are summarized in the Results section and Table 1 and representative data are provided for all patients in Figure 1.

#### Results

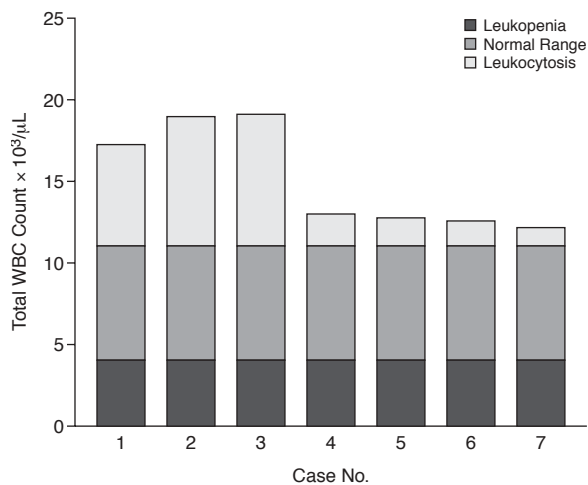
All patients in this case series are residents of nursing homes where vital signs are monitored on a regular basis by nursing staff. Patients are seen by the primary care doctor at least monthly and by the psychiatrist every 1 to 3 months. All patients have been under care of the first author (S.M.); some have been evaluated and worked up by the hematologist and coauthor (L.C.). All patients in this case series are smokers who are allowed 6 cigarettes/day. Since patients are in a structured setting, smoking is controlled. None of the patients had any active infections manifested by fever or corresponding changes in blood counts or any other common etiologic factors for leukocytosis. No patients in this case series had any bone marrow studies done, since the leukocytosis was chronic and appeared to be related to the clozapine use. No patients in this series had any adverse consequences related to the leukocytosis.

**Case 1.** Mr. A is a 42-year-old black man who has been living in the nursing home for the past 7 to 8 years. He has a history of long-term psychiatric hospitalization in a state psychiatric center. Mr. A's diagnoses at admission to the nursing home included chronic paranoid schizophrenia, mental retardation, and hyperlipidemia. He had a history of polysubstance abuse as a teenager. He was placed in the nursing home from the state hospital, where he had been taking a combination of risperidone 2 mg and clozapine 600 mg PO daily. At admission to the nursing home, risperidone was discontinued, and the clozapine dose was tapered gradually to 450 mg PO h.s. and has been maintained at that level for the past 5 years. Clozapine was originally started in 1996 at the state hospital. Mr. A is a smoker, and since being in the nursing home, is allowed 6 cigarettes per day. His WBC count was elevated prior to admission and has continued to be elevated since he has been in the nursing home. WBC counts were monitored every 2 weeks. Absolute neutrophil count has been monitored only since 2005, when the new monitoring guidelines for clozapine were implemented. WBC counts have been consistently elevated, and some representative values are shown in Table 1 and Figure 1. Mr. A continues to be monitored in the nursing home.

**Case 2.** Mr. B is a 43-year-old white man admitted to the nursing home in 2000 from a state psychiatric center. He was taking olanzapine 10 mg PO h.s. and clozapine 300 mg PO b.i.d. on admission. Olanzapine was discontinued, and Mr. B was maintained on the clozapine therapy. However, he decompensated and was hospitalized several times, after which he was placed on combination therapy of clozapine with perphenazine. Mr. B's diagnosis included chronic paranoid schizophrenia, coronary artery disease, hypertension, and peptic ulcer disease. He had no history of drug or alcohol abuse.

He had sporadic mild leukocytosis from 2000 to 2002. At the end of 2002, Mr. B had a medical hospitalization at which time clozapine and perphenazine treatment were discontinued and olanzapine therapy started. He decompensated very quickly and

Figure 1. Highest Leukocyte Counts During the Study Period



Abbreviation: WBC = white blood cell.

had to be rehospitalized psychiatrically in March 2003. His WBC counts were within normal limits when he was taken off the clozapine therapy. He was restarted on clozapine therapy in March 2003, and dosage was increased up to 550 mg/day. Mr. B was also started on sodium valproate therapy up to 500 mg PO b.i.d. WBC counts were monitored weekly for 6 months, then twice a month for the next 6 months, and on a monthly basis thereafter. During his treatment with clozapine, for the second time, Mr. B has had consistently elevated WBC counts (higher than during his earlier treatment phase). Mr. B is a smoker who is allowed 6 cigarettes per day. He showed no evidence of infection or of other common causes of leukocytosis, nor did he show any adverse effects of the leukocytosis. He continues to be monitored in the nursing home.

**Case 3.** Mr. C is a 47-year-old white man admitted to the nursing home in June 2004. He has a long history of multiple psychiatric hospitalizations in state and community hospital psychiatric units. He was started on clozapine therapy prior to 1998—exact dates are unavailable. Mr. C has a history of schizoaffective disorder and hypertension. There is no history of drug or alcohol abuse.

He has been taking clozapine, quetiapine, clonazepam, and escitalopram from admission. Mr. C's WBC counts have been consistently elevated since admission. He is a smoker who is allowed 6 cigarettes/day. He has not shown any evidence of infection or other common causes of leukocytosis. Mr. C continues to be monitored in the nursing home.

**Case 4.** Mr. D is a 52-year-old white man admitted to the nursing home in 2002. He has a history of multiple psychiatric hospitalizations and had lived in an adult home prior to his nursing home placement. He has been taking clozapine since admission. Mr. D has a history of chronic paranoid schizophrenia, hypertension, and peptic ulcer disease. He has had mild leukocytosis since admission. He has no history of drug or alcohol abuse. Mr. D is a smoker who smokes up to 6 cigarettes/day. He showed no evidence of infection or other common causes of leukocytosis, nor did he show any adverse effects of leukocytosis. Mr. D continues to be monitored in the nursing home.

**Case 5.** Mr. E is a 48-year-old white man admitted to the nursing home in November 2002. He has a history of multiple psychiatric hospitalizations for chronic paranoid schizophrenia,

seizure disorder, hypertension, and hyponatremia. He has no history of drug or alcohol abuse. Mr. E is a smoker who is allowed 6 cigarettes/day. He has been taking clozapine from admission, and his WBC counts have been consistently elevated since admission. Mr. E showed no evidence of infection or other common causes of leukocytosis, nor did he show any adverse effects of leukocytosis. Mr. E continues to be monitored in the nursing home.

**Case 6.** Mr. F is a 51-year-old black man admitted to the nursing home in February 2001. He has a history of multiple psychiatric hospitalizations for chronic undifferentiated schizophrenia. He also has a history of hypertension, cellulitis, congestive heart failure, and diabetes mellitus. He has no history of drug or alcohol abuse. His cellulitis was treated prior to placement in the nursing home. Mr. F has been taking clozapine and olanzapine from admission, and his WBC counts have been consistently elevated. He is a smoker who is allowed 6 cigarettes/day. Mr. F did not show any evidence of infection or other common causes of leukocytosis, nor did he show any adverse effects of leukocytosis. He was discharged from the nursing home in early 2004 and lost to follow-up.

**Case 7.** Mr. G is a 52-year-old black man admitted to the nursing home in June 2002. He has a history of multiple psychiatric hospitalizations in community hospital psychiatric units and state psychiatric facilities. He has a history of chronic paranoid schizophrenia and polysubstance abuse. His medical diagnoses included diabetes mellitus, hypertension, benign prostatic hypertrophy, and gastroesophageal reflux disease.

At admission to the nursing home, Mr. G was taking sodium valproate, benzotropine mesylate, haloperidol, and haloperidol decanoate. In September 2002, haloperidol was discontinued due to extrapyramidal symptoms, and he was started on quetiapine therapy up to 700 mg/day. His WBC counts during admission and yearly follow-up reports were within normal limits. Mr. G is a smoker and has been smoking about 1 to 3 cigarettes/day since placement. He was readmitted to the psychiatric unit due to worsening psychotic symptoms in May 2003. Quetiapine was discontinued, and clozapine was started; dosage was titrated to 250 mg/day. Mr. G was returned to the nursing home in early June 2003. All WBC counts up to September 2003 had been within normal limits. Leukocytosis was noted from early September 2003, when WBC counts were being monitored on a weekly basis. Clozapine was increased to 450 mg/day. Mr. G showed consistent mild leukocytosis. He showed no evidence of infection or other causes of leukocytosis, nor did he show any adverse effects of leukocytosis. Mr. G started refusing the blood work around April 2006, and clozapine was discontinued. Mr. G was started on molindone hydrochloride therapy. His WBC counts have been within normal limits since the discontinuation of clozapine. He continues to be monitored. We have been able to follow Mr. G before, during, and after treatment with clozapine. The leukocytosis was noted only during clozapine treatment.

There were 7 patients identified with chronic leukocytosis in this case series. All patients (100%) were male—4 (57%) white and 3 (43%) black. The mean age was 47.8 years (range, 42–52 years). Six patients (86%) had schizophrenia, and 1 (14%) had schizoaffective disorder. Six patients (86%) had hypertension, and 5 were taking antihypertensive medications. The mean daily dose of clozapine was 457 mg (range, 50–600 mg). The mean total WBC count was  $13.6 \times 10^3/\mu\text{L}$  (range,  $11.3$ – $19.1 \times 10^3/\mu\text{L}$ ). There were no consistent changes in the differential count. Chronic leukocytosis has been tracked for a period of 2 to 5 years in these patients (Table 1). There were no clinical consequences of the leukocytosis noted in these patients. Other

Table 1. Patient Characteristics and WBC Counts

Case No.	Age, y	Sex	Race	Psychiatric Diagnosis	Medical Diagnosis	Concurrent Medication	Clozapine dose/day or Other Psychotropic Medication	WBC		Differential Count Abnormalities <sup>a</sup>	Date
								Total Count <sup>a</sup>	Date		
1 <sup>b</sup>	42	Male	Black	Chronic paranoid schizophrenia Mental retardation	Hyperlipidemia	Lovastatin	Clozapine 450 mg	14.1 × 10 <sup>3</sup> /μL 16.1 × 10 <sup>3</sup> /μL 17.2 × 10 <sup>3</sup> /μL mean = 15.8 × 10 <sup>3</sup> /μL	11/24/99 5/24/01 4/08/03	None	
2 <sup>c</sup>	43	Male	White	Chronic paranoid schizophrenia	Coronary artery disease Hypertension Peptic ulcer disease	Atenolol Ramitidine Acetylsalicylic acid	Clozapine 550 mg Sodium valproate	13.7 × 10 <sup>3</sup> /μL 11.3 × 10 <sup>3</sup> /μL 19 × 10 <sup>3</sup> /μL mean = 14.7 × 10 <sup>3</sup> /μL	4/04/03 9/13/04 12/16/05	AN = 13 × 10 <sup>3</sup> /μL AM = 1.3 × 10 <sup>3</sup> /μL	12/16/05 12/16/05
3 <sup>d</sup>	47	Male	White	Schizoaffective disorder	Hypertension	Nisoldipine Zolpidem Trihexyphenidyl hydrochloride	Clozapine 600 mg Clonazepam Quetiapine Escitalopram	16.6 × 10 <sup>3</sup> /μL 13.1 × 10 <sup>3</sup> /μL 19.1 × 10 <sup>3</sup> /μL mean = 16.3 × 10 <sup>3</sup> /μL	6/03/04 8/25/04 1/04/06	AN = 15.0 × 10 <sup>3</sup> /μL N = 78.6% L = 14% B = 1.3%	1/4/2006
4 <sup>e</sup>	52	Male	White	Chronic paranoid schizophrenia	Hypertension Peptic ulcer disease	Atenolol Risedronate sodium	Clozapine 600 mg	11.4 × 10 <sup>3</sup> /μL 13.0 × 10 <sup>3</sup> /μL 11.4 × 10 <sup>3</sup> /μL mean = 11.9 × 10 <sup>3</sup> /μL	11/18/03 3/16/04 1/12/05	E = 0%	
5 <sup>f</sup>	48	Male	White	Chronic paranoid schizophrenia	Seizure disorder Hypertension Hyponatremia	Sodium valproate	Clozapine 600 mg	12.4 × 10 <sup>3</sup> /μL 11.9 × 10 <sup>3</sup> /μL 12.8 × 10 <sup>3</sup> /μL mean = 12.4 × 10 <sup>3</sup> /μL	11/18/03 3/16/04 1/12/05	N = 78% L = 23%	11/18/03
6 <sup>g</sup>	51	Male	Black	Chronic undifferentiated schizophrenia	Hypertension Cellulitis Congestive heart failure Diabetes mellitus	Furosemide Glipizide Verapamil	Clozapine 50 mg Olanzapine 7.5 mg	11.8 × 10 <sup>3</sup> /μL 12.6 × 10 <sup>3</sup> /μL 12.4 × 10 <sup>3</sup> /μL mean = 12.3 × 10 <sup>3</sup> /μL	9/19/02 2/24/03 1/22/04	None	
7 <sup>h</sup>	52	Male	Black	Chronic paranoid schizophrenia	Diabetes mellitus Hypertension Benign prostatic hypertrophy Gastroesophageal reflux disease	Nisoldipine Lovastatin Metformin Glipizide Terazosin Omeprazole Ibuprofen	Clozapine 450 mg Valproic acid	12.2 × 10 <sup>3</sup> /μL 11.5 × 10 <sup>3</sup> /μL 11.3 × 10 <sup>3</sup> /μL mean = 11.7 × 10 <sup>3</sup> /μL	9/03 3/04 1/06	AE = 0.1 × 10 <sup>3</sup> /μL E = 0.9%	01/06

<sup>a</sup>Normal values: AE = 0 to 0.7 × 10<sup>3</sup>/μL, AM = 0.1 to 1.0 × 10<sup>3</sup>/μL, AN = 1.6 to 7.8 × 10<sup>3</sup>/μL, B = 0% to 1.0%, E = 1.0% to 4.0%, L = 20.0% to 40.0%, M = 2.0% to 10.0%, N = 40.0% to 70.0%.

<sup>b</sup>Clozapine started 8/96. WBC = 19.8 × 10<sup>3</sup>/μL (12/05), AN = 9.4 × 10<sup>3</sup>/μL. AL = 5.0 × 10<sup>3</sup>/μL.

<sup>c</sup>Clozapine started 03/03.

<sup>d</sup>Clozapine started before 1998.

<sup>e</sup>Clozapine started before 2003.

<sup>f</sup>Clozapine started before 2003.

<sup>g</sup>Clozapine started before 2002.

<sup>h</sup>Clozapine started 06/03.

Abbreviations: AE = absolute eosinophil count, AL = absolute lymphocyte count, AM = absolute monocyte count, AN = absolute neutrophil count, B = basophil count, E = eosinophil count, L = lymphocyte count, M = monocyte count, N = neutrophil count, WBC = white blood cell.



etiologic factors for leukocytosis in these patients were ruled out. In 2 patients (cases 2 and 7) in whom clozapine was discontinued for a short period, leukocytosis resolved, and only to return in case 2 when clozapine was restarted.

### Discussion

A number of factors routinely cause leukocytosis: relatively benign conditions like infection; inflammatory response to tissue necrosis, infarction, burns, and arthritis; stress-related situations like overexertion, seizures, anxiety, and anesthesia; drugs like corticosteroids, lithium, and  $\beta$  agonists; and trauma (e.g., splenectomy). When WBC counts are extremely elevated or there are concurrent abnormalities in red blood cells or platelet counts, primary bone marrow disorders should be suspected. As Abramson et al. characterize it, "The circulating pool of neutrophils is divided into 2 classes. One pool of cells is circulating freely and the second pool deposited along the margins of blood vessel walls. In response to infection, inflammation, drugs or metabolic toxins, the deposited cells 'demarginate' and enter the freely circulating pool."<sup>5(p2054)</sup> Further discussion of the hematologic literature is beyond the scope of this article.

Reports of chronic leukocytosis associated with clozapine have been noted only rarely in the literature. Several database analyses of the clozapine monitoring system and hospital records have reported transient leukocytosis at rates ranging from 6.7% to 52%.<sup>7-10</sup> The transient leukocytosis is reported to be clinically benign in all these studies. It is interesting to note that all these studies were done in Europe or China. There is 1 case of chronic leukocytosis reported in the Austrian study.<sup>1</sup> Demographic breakdown of patients with transient leukocytosis was not reported in these studies, since all of them looked at either all side effects or all hematologic side effects associated with clozapine use. While leukopenia, agranulocytosis, and eosinophilia are potentially lethal hematologic side effects associated with clozapine use, leukocytosis associated with clozapine, whether transient or chronic, appears to be benign, based on the reported cases.<sup>11-15</sup>

The etiology of leukocytosis associated with clozapine use is unknown. There are sporadic reports of leukocytosis associated with clozapine use.<sup>11-15</sup> In the report by Seifritz et al.,<sup>11</sup> the leukocytosis was thought to be secondary to rehabilitation stress. A case report of persistent leukocytosis associated with clozapine by Trinidad et al. is complicated by the concurrent use of lithium.<sup>14</sup> In the case reported by Popli and Pies,<sup>12</sup> the patient had had a splenectomy, which could have contributed to the leukocytosis.

A recent case of persistent leukocytosis associated with clozapine use, and followed up for over 10 months, has been reported.<sup>15</sup> Even though a thorough medical workup did not identify any causative factors in this case, the patient is reported to be a chronic smoker, using 20 to 30 cigarettes daily.<sup>15</sup> High smoking rate is associated with an increase in WBC count.<sup>6,16</sup> Chronic smoking causes phenotypic changes in circulating polymorphonuclear leukocytes that are characteristic of chronic stimulation of the bone marrow.<sup>16</sup> Animal studies have shown that chronic smoking shortens the transit time of polymorphonuclear leukocytes through the bone marrow.<sup>16</sup>

Leukopenia and agranulocytosis associated with clozapine use have been investigated extensively. Neutropenia associated with clozapine is thought to be secondary to a cytotoxic effect on the committed progenitor cell compartment but not on primitive hematopoietic cells.<sup>17</sup> The risk for agranulocytosis appears elevated in the elderly, women, and patients of Ashkenazi Jewish descent with HLA-B38 phenotype.<sup>18</sup>

The etiology and risk factors for leukocytosis associated with clozapine are unknown. In our small case series of 7 pa-

tients, there is no significant difference in racial distribution. Interestingly, all patients were males between the ages of 42 and 52 years. Male sex may be a risk factor for leukocytosis. All patients reported in the literature with chronic or persistent leukocytosis associated with clozapine use are male.<sup>11,12,14,15</sup> Eighty-six percent of patients had schizophrenia. None of the patients had any medical illnesses with known propensity to cause leukocytosis. None of the concurrent medications patients were taking are known to cause leukocytosis except omeprazole, in rare instances.<sup>7</sup> However, the patient who was taking omeprazole showed no evidence of leukocytosis prior to clozapine treatment despite taking omeprazole.

Most of the concurrent medications listed in Table 1 can cause leukopenia/agranulocytosis in rare instances.<sup>7</sup> Lovastatin can cause eosinophilia in rare instances.<sup>7</sup> The patient who was taking lovastatin did not have eosinophilia according to the differential count (Table 1). Six of our patients had hypertension, and 5 were taking antihypertensive medications. All patients in our case series are smokers. However, they are in structured environments where they are allowed a maximum of only 6 cigarettes/day. In the 2 cases in which we were able to track the WBC counts from the beginning of clozapine treatment, the leukocytosis was noted first after 1 to 3 months of clozapine treatment. No leukocytosis was noted in these 2 patients prior to clozapine treatment, even though they were smokers, or after clozapine was discontinued. Mr. G was followed with blood counts before, during, and after treatment with clozapine. The leukocytosis was noted only during clozapine treatment, which suggests a possible association. Mr. A has been noted to have leukocytosis for more than 5 years. None of our patients had any clinical consequences associated with the leukocytosis.

The limitations of this study include the small sample size, retrospective design, smoking status of the patients, and lack of a control group.

### Conclusion

Chronic leukocytosis, even though infrequent, appears to be a potential side effect of clozapine, and it is generally benign. Long-term analysis of the clozapine monitoring system data will be of help in further investigating this issue.

*This study was not supported by any external funding.*

*Dr. Madhusoodanan is a consultant for Bristol-Myers Squibb and AstraZeneca; has received grant/research support from AstraZeneca, Janssen, and Eli Lilly; and serves on the speakers/advisory boards for Bristol-Myers Squibb and AstraZeneca. Dr. Brenner has received grant/research support from Janssen, Eli Lilly, AstraZeneca, Pfizer, and Bristol-Myers Squibb and serves on the speakers/advisory boards for Janssen, Eli Lilly, and Pfizer. Dr. Sajatovic serves as a consultant for AstraZeneca and GlaxoSmithKline, has received grant/research support from Abbott and Bristol-Myers Squibb, and has received honoraria from and serves on the speakers/advisory board for AstraZeneca. Drs. Cuni, Palekar, and Amanbekoya report no financial affiliation or other relationship relevant to the subject of this letter.*

### REFERENCES

1. Hammer M, Kurz M, Barnes C, et al. Clozapine induced transient white blood count disorders. *J Clin Psychiatry* 1994; 55:429-432
2. Shapiro MF, Greenfield S. The complete blood count and leukocyte differential count: an approach to their rational application. *Ann Intern Med* 1987;106:65-74
3. McCarthy DA, Perry JD, Melson RD, et al. Leucocytosis induced by exercise. *Br Med J* 1987;295:636
4. Darko DF, Rose J, Gillin JC, et al. Neutrophilia and lymphopenia in major mood disorders. *Psychiatry Res* 1988;25:243-251
5. Abramson N, Melton B. Leukocytosis: basics of clinical assessment. *Am Fam Physician* 2000;62:2053-2060

6. Parry H, Cohen S, Schlarb JE, et al. Smoking, alcohol consumption and leukocyte counts. *Am J Clin Pathol* 1997;107:64–67
7. Clozaril [clozapine]. Physicians' Desk Reference. Montvale, NJ: Thomson Healthcare; 2005:2280–2285
8. Panteleeva GP, Kovskaya MY, Belyaev BS, et al. Clozapine in the treatment of schizophrenic patients: an international multicenter trial. *Clin Ther* 1987;10:57–68
9. Lu MK. Clinical analysis in the main side effects of clozapine: enclosed 600 cases report [in Chinese]. *Zhonghua Shen Jing Jing shen Ke ZA Zhi* 1991;71–74, 123
10. Lambertenghi Delilieri GK. Blood dyscrasias in clozapine-treated patients in Italy. *Haematologica* 2000;85:233–237
11. Seifritz E, Hemmeter U, Holsboer-Trachsler E, et al. Chronic leukocytosis and neutrophilia caused by rehabilitation stress in a clozapine treated patient. *Pharmacopsychiatry* 1993;26:99
12. Popli A, Pies R. Clozapine and leukocytosis. *J Clin Psychopharmacology* 1995;15:286–287
13. Sajatovic M, Madhusoodanan S, Fuller MA. Clozapine for schizophrenia. In: Mueser KT, Jeste DV, eds. *Clinical Handbook of Schizophrenia*. New York, NY: Guilford Press. In press
14. Trinidad ED, Potti A, Mehdi SA. Clozapine-induced blood dyscrasias. *Haematologica* 2000;85:E02
15. Sundaram L, Croos R, Davis JDR, et al. Chronic leukocytosis in a patient treated with clozapine. *Prog Neurol Psychiatry* 2005;9
16. Eeden SFV, Hogg JC. The response of human bone marrow to chronic cigarette smoking. *Eur Respir J* 2000;15:915–921
17. Delilieri GL, Servida F, Lamorte G, et al. In vitro effect of clozapine on hemopoietic progenitor cells. *Haematologica* 1998;83:882–889
18. Alvir MJM, Lieberman JA, Saferman AZ, et al. Clozapine-induced agranulocytosis. *N Eng J Med* 1993;329:162–167

**Subramoniam Madhusoodanan, M.D.**

**Louis Cuni, M.D.**

**Ronald Brenner, M.D.**

St. John's Episcopal Hospital

Far Rockaway, New York

**Martha Sajatovic, M.D.**

Case Western Reserve University School of Medicine

Cleveland, Ohio

**Nikhil Palekar, M.D.**

**Dinara Amanbekova, M.D.**

S.U.N.Y., Health Science Center at Brooklyn, New York

Brooklyn, New York

## Occurrence of Reversible Bilateral Scotoma 1 Hour After Single-Pulse Transcranial Magnetic Stimulation: A Case Report

**Sir:** Transcranial magnetic stimulation (TMS) is a non-invasive method for stimulating predefined areas of the cortex. It not only is used as a neurologic technique to measure connectivity and excitability of the cortex by magnetic stimulation, but also has clear effects if added to the standard treatment of psychiatric diseases.<sup>1,2</sup> The activation of neural tissue by TMS is not limited to the stimulated cortical area but can also spread to connected intralateral and contralateral structures.<sup>3</sup> This activation of neuronal networks can be measured by brain imaging methods.<sup>4,5</sup> Adverse effects of TMS<sup>6,7</sup> are, especially when using single-pulse TMS, very unlikely.<sup>8</sup> Nevertheless, we examined a healthy subject who developed a reversible bilateral flicker scotoma 1 hour after TMS over the motor area of the right abductor pollicis brevis muscle.

**Case report.** Mr. A, a 30-year-old man, participated in our as-yet unpublished study combining TMS and multichannel near-infrared spectroscopy (NIRS) as a healthy participant in

April 2006. He had no history of seizures or migraine. He consumed no medications, excessive caffeine, or nicotine for at least 1 week prior to TMS.

For the TMS-NIRS study, we used a Medtronic MagPro X100 TMS apparatus with a figure-of-eight coil (diameter: 70 mm, pulses: biphasic, current: posterior-anterior; Medtronic, Duesseldorf, Germany.). The stimulation consisted of 3 runs with 40 stimuli each. First, the subject received sham stimulation with no magnetic field generation; then, resting motor threshold of the right abductor pollicis brevis muscle was defined.<sup>9</sup> Afterward, we stimulated at 110% and 130% resting motor threshold over the left motor cortex. The 52-channel NIRS probe set was placed over the right motor cortex to measure changes of oxyhemoglobin and deoxyhemoglobin concentrations contralateral to stimulation site.

One hour after TMS, the participant developed a bilateral centrally localized flicker scotoma he had never experienced before. This visual phenomenon was scintillating and emerged gradually. Neither zigzag lines nor an aura around the scotoma were described. During its course, the scotoma spread to the right superior quadrant of the field of vision. Maximum of symptoms was reached 1 hour after their beginning. The symptoms abated completely after 4 hours.

We sought to determine what caused the scotoma. Symptom arising from NIRS itself or by an interaction with TMS can be excluded because NIRS uses innocuous near-infrared light, which does not cause effects in neuronal tissue or interactions with electrical or magnetic fields.<sup>10</sup> To determine if this reversible scotoma was associated with some neurologic pathology, we conducted clinical electroencephalography (EEG) and structural magnetic resonance imaging (MRI). Additionally, we classified the symptoms using the Visual Aura Rating Scale (VARS),<sup>11</sup> a diagnostic tool for migraine with aura that consists of 5 visual symptom characteristics: duration of 5 to 60 minutes (3 points), gradual development  $\geq$  5 minutes (2 points), scotoma (2 points), zigzag lines (2 points), and unilateral (1 point). A score of more than 5 points in the VARS is an indication of a migraine with aura. However, no abnormalities were found in any of these examinations.

Schulze-Bonhage<sup>12</sup> described the differential diagnosis of visual aura in migraine and epilepsy. Visual phenomena like unilateral, temporary scotoma can emerge in both migraine and epilepsy.<sup>13</sup> Given the existing EEG, MRI, and VARS data for Mr. A together with his exact report of the symptoms, the likelihood of a migraine-like or seizure-like background is very low.

It is known that single-pulse TMS can provoke headache during or after stimulation. Up to now, the occurrence of a flicker scotoma has not been described. An explanation for this phenomenon could be that the area of the hand motor cortex is in some individuals located near the frontal eye field,<sup>14</sup> which promotes the function of eye movement<sup>15</sup> and projects to cortical and subcortical regions involved in visual processing.<sup>16</sup> Because of these projections, TMS over the frontal eye field could affect visual processing mechanisms in distant cortical areas.<sup>17</sup> We assume that we unwittingly stimulated parts of the frontal eye field, which caused the described scotoma via the visual cortex.

Even though it is still unclear if the origin of the flicker scotoma resulted from TMS, this adverse effect should be kept in mind for future studies.

*Supported by grant KFO 125/1-1 from the Deutsche Forschungsgemeinschaft (German Research Community).*

*The authors report no financial or other affiliation relevant to the subject of this letter.*

## REFERENCES

1. Haag C, Padberg F, Moller HJ, et al. Transkranielle Magnetstimulation (TMS). *Nervenarzt* 1997;68:274–278
2. Daskalakis ZJ, Christensen BK, Fitzgerald PB, et al. Transcranial magnetic stimulation: a new investigational and treatment tool in psychiatry. *J Neuropsychiatry Clin Neurosci* 2002;14:406–415
3. Fuggetta G, Fiaschi A, Manganotti P. Modulation of cortical oscillatory activities induced by varying single-pulse transcranial magnetic stimulation intensity over the left primary motor area: a combined EEG and TMS study. *Neuroimage* 2005;27:896–908
4. Ilmoniemi R, Virtanen J, Ruohonen J, et al. Neuronal response to magnetic stimulation reveal cortical reactivity and connectivity. *Neuroreport* 1997;8:3537–3540
5. Bestmann S, Baudewig J, Siebner HR, et al. BOLD MRI responses to repetitive TMS over human dorsal premotor cortex. *Neuroimage* 2005;28:22–29
6. Pascual-Leone A, Valls-Sole J, Brasil-Neto JP, et al. Seizure induction and transcranial magnetic stimulation [letter]. *Lancet* 1992;339:997
7. Tharayil B, Gangadhar B, Thirthalli J, et al. Seizure with single-pulse transcranial magnetic stimulation in a 35-year-old otherwise healthy patient with bipolar disorder. *J ECT* 2005;21:188–189
8. Wassermann E. Risk and safety of repetitive transcranial magnetic stimulation: report and suggested guidelines from the International Workshop on the Safety of Repetitive Transcranial Magnetic Stimulation, June 5–7, 1996. *Electroencephalogr Clin Neurophysiol* 1998;108:1–16
9. Rossini PM, Barker AT, Berardelli A, et al. Non-invasive electrical and magnetic stimulation of the brain, spinal cord and roots: basic principles and procedures for routine clinical application. Report of an IFCN committee. *Electroencephalogr Clin Neurophysiol* 1994;91:79–92
10. Strangman G, Boas DA, Sutton JP. Non-invasive neuroimaging using near-infrared light. *Biol Psychiatry* 2002;52:679–693
11. Eriksen M, Thomsen L, Olesen J. The Visual Aura Rating Scale (VARs) for migraine aura diagnosis. *Cephalalgia* 2005;25:801–810
12. Schulze-Bonhage A. Differential diagnosis of visual aura in migraine and epilepsy. *Klin Monatsbl Augenheilkd* 2001;218:595–602
13. Basser L. The relation of migraine and epilepsy. *Brain* 1969;92:285–300
14. Amiez C, Kostopoulos P, Champod AS, et al. Local morphology predicts functional organization of the dorsal premotor region in the human brain. *J Neurosci* 2006;26:2724–2731
15. Bruce CJ, Goldberg ME, Bushnell MC, et al. Primate frontal eye fields, 2: physiological and anatomical correlates of electrically evoked eye movements. *J Neurophysiol* 1985;54:714–734
16. Goldberg M. The control of gaze. In: Kandel ER, Schwartz JH, Jessel TM, eds. *Principles of Neural Science*. 4th ed. New York, NY: McGraw-Hill; 2000:782–798
17. Taylor PC, Nobre A, et al. FEF TMS Affects Visual Cortical Activity. *Cerebral Cortex* 2006. Epub ahead of print

**Kathrin C. Zierhut, M.Sc.**

**Melany M. Richter, M.A.**

Laboratory of Psychophysiology and Functional Imaging  
Department of Psychiatry and Psychotherapy

**Tobias J. Renner, M.D.**

Department of Child and Adolescent  
Psychiatry and Psychotherapy

**Andreas J. Fallgatter**

Laboratory of Psychophysiology and Functional Imaging  
Department of Psychiatry and Psychotherapy

University of Wuerzburg

Wuerzburg, Germany

---

### Correction

In the letter to the editor “Methadone Hydrochloride to Prevent Impulsive Behavior in Mental Retardation: A Case Report” by Abdullah M. Hasan, M.D., et al. (December 2006 issue, pp. 2032–2033), the order of authorship should have been Abdullah M. Hasan, M.D.; Michael B. Bernstein, B.S.; GERALYNN Marchesi, N.P.P.; Elizabeth Lesser, M.S.W.; Mark Russ, M.D.; Arthur Rifkin, M.D.; and Alan J. Mendelowitz, M.D. The online version of the article has been corrected.

The CME Institute of Physicians Postgraduate Press, Inc., is accredited by the Accreditation Council for Continuing Medical Education to provide continuing medical education for physicians. This activity was supported by an educational grant from Bristol-Myers Squibb Company.