

Letters to the Editor

Remission of SSRI-Induced Akathisia After Switch to Nefazodone

Sir: Akathisia may be defined as the subjective feeling of muscle discomfort usually manifesting as a result of treatment with antipsychotic medication. Moreover, the subjective experience is often associated with objective symptomatology such as restless leg movements, walking to and fro, and inability to sit in one place for an extended period of time. This undesirable side effect frequently expresses itself as a formidable therapeutic challenge. While akathisia is most commonly expressed following the use of antipsychotic medication, often it may be observed resulting from the use of antidepressant therapy, in particular drugs of the selective serotonin reuptake inhibitor (SSRI) class expressing serotonin-2A (5-HT_{2A}) stimulatory effects.¹⁻⁶ Various reports have estimated the occurrence rate of this phenomenon of SSRI-induced akathisia to range from 9.8% to 45.1%.^{4,7,8}

The subjective discomfort experienced by the patient with akathisia is frequently disabling and of significant severity to the extent that it may even lead to suicidal behavior.⁹⁻¹³ Furthermore, akathisia often results in treatment noncompliance following the inability to tolerate the psychotropic medication.^{14,15}

Nefazodone is an antidepressant with both presynaptic serotonin and norepinephrine reuptake properties as well as postsynaptic 5-HT_{2A} blockade characteristics.¹⁶ Considering its relatively unique receptor activity profile, we hypothesize that the medication will demonstrate beneficial effects in the reduction of akathisia symptomatology. To our knowledge, we present here the first reports of the utility of nefazodone in managing disabling akathisia following SSRI medication management. In these case reports, we demonstrate the marked and rapid improvement in akathisia symptomatology after a switch to treatment with nefazodone.

Case 1. Ms. A, a 40-year-old woman with no previous psychiatric or medical history, presented for the management of symptomatology consistent with a diagnosis of major depression (DSM-IV criteria). Treatment with paroxetine, 20 mg/day, was initiated. Following full remission of symptomatology after 1 month, treatment was maintained for a further 7 months, after which it was discontinued.

A year after discontinuation of paroxetine treatment, Ms. A presented with symptoms of moderate depression, accompanied by mild anxiety. Treatment with paroxetine was reinstated at the same dose. Two weeks after paroxetine reinitiation, a marked improvement in depressive symptomatology was observed; however, she presented with complaints of difficulty sitting in one place for any length of time, restless leg movements that precluded her attempts to fall asleep at night, and "inner restlessness," the nature of which she had never experienced. These subjective complaints were assessed as being classic symptomatology of akathisia. At this time, Ms. A was also taking atenolol, 25 mg/day, initiated several months previously for

management of high blood pressure. Oxazepam, 30 mg/day, was prescribed for the management of these paroxetine-induced akathisia symptoms. However, in light of her inability to tolerate oxazepam due to persistent fatigue and resulting difficulty in functional ability, paroxetine was discontinued and replaced with nefazodone, 300 mg/day. With the initiation of nefazodone, Ms. A experienced a complete resolution of symptoms of akathisia as well as those of depression, and within a few days she returned to full baseline functioning and activities.

Case 2. Ms. B, a 40-year-old woman, was hospitalized for the first time in a psychiatric institution following complaints of a 2-week history of severe agitation, verbal aggression, and a subsequent decrease in ability to maintain her previous level of daily functioning. Associated with these symptoms was an inability to sit still for any period of time. These symptoms appeared a few days after the initiation of fluoxetine, 20 mg/day, prescribed for depressive ideation that had progressively worsened over several months. At the time of admission, she remained significantly dysphoric, with vegetative symptoms of depression including early morning awakening and diminished appetite. After admission, fluoxetine was discontinued, and nefazodone was initiated with titration up to 400 mg/day. Within a few days, the agitation and restlessness completely resolved. Two weeks after admission, Ms. B was discharged home. Three weeks after discharge, all depressive symptoms resolved, and she returned to full baseline function. It should be emphasized that following the initiation of nefazodone, the patient experienced a full remission of symptoms of akathisia.

While symptoms of akathisia are classically described as side effects of antipsychotic medications, disabling symptoms of akathisia may also be observed accompanying management with antidepressant medication of the tricyclic (TCA) and SSRI types. The precise pathophysiology of akathisia remains poorly understood; however, it has been suggested that akathisia results from inhibition of dopaminergic neurons in the ventral tegmental area (VTA) and by means of activity at the postsynaptic β -adrenergic and serotonergic (5-HT_{2A}) receptors.⁴ This hypothesis of akathisia with reference to the serotonergic system has come to light particularly since the introduction of TCA and SSRI medications into clinical practice. These medications lead to an increase of these catecholaminergic and serotonergic neurotransmitters in the synaptic space. Since akathisia is a syndrome related to a subjective experience of discomfort that may markedly disturb patients and may even lead to suicidal tendencies, a rapid method of management becomes considerably important.

The management of antidepressant-induced akathisia includes dose reduction and the addition of several various other medications such as β -blockers, anticholinergics, antihistamines, and benzodiazepines.¹⁷ Alternate management options include the administration of other antidepressant medications with which medication-induced risk is minimal. Nefazodone, a relatively new antidepressant medication that is not accompa-

nied by akathisia side effects, meets these demands. While nefazodone, like SSRIs, acts presynaptically by inhibiting serotonin reuptake and thus may potentially induce akathisia as described in a previous single case report,¹⁸ it appears that its predominant effect of postsynaptic 5-HT_{2A} antagonism determines the final effect between these 2 opposing actions. This latter action is thought to result in augmentation of VTA dopaminergic activity, thus lessening the subsequent appearance of undesirable akathisia. This model of receptor activity is further supported by other 5-HT_{2A} antagonists, including cyproheptadine¹⁹ and ritanserin.²⁰

The 2 patients described above with disabling SSRI-induced akathisia both experienced rapid alleviation of the side effect following a switch to nefazodone. While it may be suggested that the abatement of akathisia symptoms was as a result of discontinuing the SSRI, we hypothesize, based on the relatively unique mechanism of nefazodone receptor activity, that it is the 5-HT_{2A} antagonistic activity as described that resulted in this dramatic improvement.

The option of switching to nefazodone has a number of advantages. In addition to its primary anti-akathisia activity as suggested above, it reduces the need for dose reduction of the SSRI (which may be attempted to reduce akathisia) and thus lessens the risk of relapse. Furthermore, it reduces the number of medications the patients would require, i.e., no anti-akathisia medication would be needed, and thus would potentially improve compliance. Our observations thus suggest that should a patient develop akathisia while being treated with an SSRI, nefazodone is an appropriate alternative antidepressant medication, with an apparent low risk for akathisia. These 2 case reports provide only limited evidence of the benefits of nefazodone under these conditions; further studies are clearly warranted to test this hypothesis under double-blind conditions.

REFERENCES

1. Hoaken DSS. An alert to extrapyramidal side-effects from SSRIs [letter]. *Can J Psychiatry* 1995;40:51
2. Adler LA, Angrist BM. Paroxetine and akathisia. *Biol Psychiatry* 1995;37:336–337
3. Altshuler LL, Pierre JM, Ames D. Sertraline and akathisia. *Clin Psychopharmacol* 1994;14:278–279
4. Lipinsky JF Jr, Mallya G, Zimmerman P, et al. Fluoxetine-induced akathisia: clinical and theoretical implications. *J Clin Psychiatry* 1989;50:339–342
5. Baldwin D, Fineberg N, Montgomery S. Fluoxetine, fluvoxamine and extrapyramidal tract disorders. *Int Clin Psychopharmacol* 1991; 6:51–58
6. Miller CH, Fleishacker WW, Elmann H, et al. Treatment of neuroleptic-induced akathisia with the 5HT₂ antagonist ritanserin. *Psychopharmacol Bull* 1990;26:373–376
7. Gerber PE, Lynd LD. Selective serotonin reuptake inhibitor-induced movement disorders. *Ann Pharmacother* 1998;32:692–698
8. Leo RJ. Movement disorders associated with the serotonin selective reuptake inhibitors. *J Clin Psychiatry* 1996;57:449–454
9. Wirshing WC, Van Putten T, Rosenberg J, et al. Fluoxetine, akathisia and suicidality: is there a causal connection? *Arch Gen Psychiatry* 1992;49:580–581
10. Power AC, Cowen PJ. Fluoxetine and suicidal behavior: some clinical and theoretical aspects of controversy. *Br J Psychiatry* 1992;161: 735–741
11. Rothschild AJ, Locke CA. Reexposure to fluoxetine after serious suicide attempts by three patients: the role of akathisia. *J Clin Psychiatry* 1991;52:491–493
12. Shear MK, Frances A, Weiden P. Suicide associated with akathisia and depot fluphenazine treatment. *J Clin Psychopharmacol* 1983;3:235–236
13. Drake RE, Ehrlich J. Suicide associated with akathisia. *Am J Psychiatry* 1985;142:499–501
14. Nierenberg AA, Cole JO. Antidepressant-adverse drug reactions. *J Clin Psychiatry* 1991;52(6, suppl):40–47
15. Fawcett J, Marcus RN, Anton SF, et al. Response of anxiety and agitation symptoms during nefazodone treatment of major depression. *J Clin Psychiatry* 1995;56(suppl 6):37–42
16. Eison AS, Eison MS, Torrente JR, et al. Nefazodone: preclinical pharmacology of a new antidepressant. *Psychopharmacol Bull* 1990;26:315–335
17. Gelenberg AJ, Bassuk EL. *The Practitioners Guide to Psychoactive Drugs*. New York, NY: Plenum Medical Book Co; 1997
18. Eberstein S, Adler LA, Angrist B. Nefazodone and akathisia. *Biol Psychiatry* 1996;40:798–799
19. Weiss D, Aizenberg D, Hermesh H, et al. Cyproheptadine treatment in neuroleptic-induced akathisia. *Br J Psychiatry* 1995;167:483–486
20. Ceulemans DL, Hoppenbrouwers ML, Gelders YG, et al. The influence of ritanserin, a serotonin antagonist in anxiety disorders: a double-blind placebo-controlled study versus lorazepam. *Pharmacopsychiatry* 1985;18:303–305

Joseph Chelben, M.D.
Rael D. Strous, M.D.
Michal Lustig, M.D.
Yehuda Baruch, M.D.

Beer Yaakov Mental Health Center
Sackler School of Medicine, Tel Aviv University
Tel Aviv, Israel

Chronic Assaultive Behavior Improved With Sleep Apnea Treatment

Sir: Obstructive sleep apnea is a cessation of breathing during rapid eye movement (REM) sleep caused by collapse or blocking of the airway. Often occurring in obese, middle-aged men, sleep apnea may lead to behavioral and cognitive impairments in individuals with schizophrenia. We present the case of a male schizophrenic patient who experienced a dramatic reduction in assaultive behavior following treatment of previously unrecognized obstructive sleep apnea.

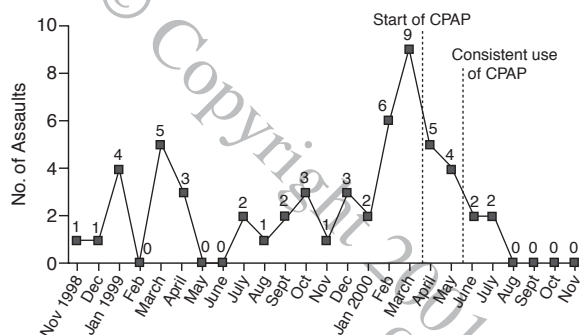
Case report. Mr. A, a 38-year-old white man with a DSM-IV diagnosis of schizoaffective disorder and an extensive history of violent and assaultive behavior, first developed symptoms of schizophrenia while in his senior year of high school and was first hospitalized for psychiatric treatment at the age of 22 years. Family history revealed that 1 sister has bipolar disorder and that a maternal grandmother and paternal aunt and uncle reportedly may have had schizophrenia. Mr. A was hospitalized in 1983 and 1985 and, since 1988, has only been out of the state hospital for 11 days on a failed release attempt. Intelligence testing in November 1999 using the Wechsler Adult Intelligence Scale-Revised showed his performance IQ to be 22 points below his verbal IQ, with severe reductions in auditory and visual memory.

Mr. A's course of treatment at the Arizona State Hospital has been complicated by extensive and unrelenting aggression and violent, physically assaultive behavior, which has resulted in long periods of frequent and continuous utilization of seclusion and restraint and in numerous significant patient and staff injuries. He frequently responds to command auditory hallucinations to assault others. He is persistently delusional about "winning" and "making points" when he assaults. He has shown signs of significant cognitive deterioration over the course of hospitalization. Since 1990, annual psychiatric evaluations have shown mental status changes, with impaired ability to complete 3-object, short-term memory testing. Mr. A had undergone extensive trials of psychotropic medications, including

Table 1. Polysomnographic Data Before and After CPAP Titration^a

Time of Polysomnography	Total Sleep Time, min	Percentage of Sleep Time				REM Sleep	No. of Hypopnea Episodes	Apnea Hypopnea Index	Average O ₂ Saturation, %	Lowest O ₂ Saturation, %
		Stage 1	Stage 2	Stage 3-4	REM Sleep					
Before CPAP	272	56	36	0	7	656	168	83	51	
After CPAP	454	2	73	0	25	10	0	94	83	

^aAbbreviations: CPAP = continuous positive air pressure, REM = rapid eye movement.

Figure 1. Number of Assaults by Month^a

^aAbbreviation: CPAP = continuous positive air pressure. Assaults include both patient-on-patient and patient-on-staff assaults.

numerous typical antipsychotic medications, mood stabilizers, and anxiolytics. He had adequate trials of high-dose risperidone, quetiapine, and clozapine, with a minimum of 18 months to 3 years per trial.

In November 1999, his medications included quetiapine, 800 mg/day; lithium carbonate, 900 mg/day; and valproic acid, 1500 mg/day. At that time, Mr. A was first noted to be falling asleep repeatedly during the day, snoring and drooling when he slept. Cognitive functions had gradually declined to the point where he found it difficult to remember staff names and significant events. Diazepam, 15 mg/day, was tapered and discontinued. In February 2000, pulse oximetry consistently showed a decrease in O₂ saturation to as low as 56% while he was sleeping. Brain magnetic resonance imaging showed no abnormalities, nor did an ear, nose, and throat consultation.

In March 2000, polysomnography showed extensive abnormalities, with only 2 hours of restful sleep. Most sleep was stage 1 or 2, with no stage 3 or 4 sleep. Mr. A's apnea hypopnea index (AHI) was 168 (normal range, 0–7; severe range ≥ 30). Oxygen saturations were less than 90% for over two thirds of the time and less than 70% for 10% of the time. Two days later continuous positive air pressure (CPAP) titration was completed, which resulted in improvement of the AHI to 0. Oxygen saturation stayed over 90%, with deeper levels of sleep attained, and increased REM sleep (Table 1). In December, Mr. A was 5'10" and weighed 268 lb (120.6 kg). His weight varied up to 281 lb (126.5 kg) in April 2000 and down to 272 lb (122.4 kg) in August 2000.

Although Mr. A initially had some difficulties with noncompliance with the CPAP treatment, he is now fully compliant with wearing the CPAP and is able to self-monitor his use of the equipment. His mental status has dramatically improved. He is generally far more alert, responsive, and active in the unit milieu. He is better able to learn and remember, and he is again

able to accurately complete 3-object memory recall on examination. Formal intellectual testing was not repeated prior to CPAP treatment or thereafter. His mood and affect have improved, with a decrease in hostility and aggression. After years of assaultive behavior despite numerous medication trials and extensive use of restrictive behavioral interventions, Mr. A is now better able to withdraw himself from getting involved in other incidents on the unit. Since the institution of CPAP treatment, he has had his longest assault-free periods in recent years. He had no assaultive incidents from mid-May to mid-June, 2000, and from mid-July onward to the date of this report (December 2000) (Figure 1). No contributing factors other than improvement in assaultive behavior due to the recognition and treatment of Mr. A's severe obstructive sleep apnea have been determined to account for the outcome of this case.

This case report is most relevant in comparison to the limited literature available on the subject of sleep apnea and adverse clinical outcomes in schizophrenic patients. A 1992 study of psychopathologic symptoms in sleep apnea patients¹ showed that Minnesota Multiphasic Personality Inventory clinical scale scores were significantly improved with CPAP treatment for a group of individuals with severe psychosocial maladjustment. Changes were remarkably significant after 1 year of CPAP treatment.

A 1998 study of 101 schizophrenic patients² showed that the prevalence of sleep-related respiratory disorders was 21.9% for men and 13.5% for women, similar to findings for a control group of healthy volunteers. We found no studies that have addressed the specific behavioral issues and outcomes of treatment for schizophrenic patients with severe sleep apnea.

The case findings reported here provide a basis for psychiatric clinicians to be more aware of the possible additional behavioral and cognitive impairments that sleep apnea may cause in chronic schizophrenic patients. The identification and treatment of sleep apnea syndrome may result in significantly improved functional outcomes for chronic schizophrenic patients.

The authors acknowledge the assistance of Kate Warburton, M.S., and Roger Warburton, M.S., from Midwestern University, Arizona College of Osteopathic Medicine, Glendale, Ariz., in gathering data, completing the record review, and preparing the preliminary draft of the letter.

REFERENCES

- Ramos Platon MJ, Espinar Sierra J. Changes in psychopathological symptoms in sleep apnea patients after treatment with nasal continuous positive airway pressure. *Int J Neurosci* 1992;62:173–195
- Takahashi KI, Shimizu T, Sugita T, et al. Prevalence of sleep-related respiratory disorders in 101 schizophrenic inpatients. *Psychiatry Clin Neurosci* 1998;52:229–231

Jerry L. Dennis, M.D.
Kevin P. Crisham, M.D.
Arizona State Hospital
Phoenix, Arizona

Negative Symptoms of Schizophrenia Are Improved by Paroxetine Added to Neuroleptics: A Pilot Study

Sir: Conventional antipsychotic drugs are highly effective in alleviating positive symptoms in schizophrenia, but they have little impact on primary negative symptoms such as apathy, social withdrawal, blunted affect, and motor retardation.^{1,2} Atypical neuroleptics could only bridge part of this treatment gap. In the 1970s, tricyclic and tetracyclic antidepressants were added to antipsychotic treatment in chronic schizophrenia, but none improved negative symptoms consistently.^{3,4} Since the early 1990s, selective serotonin reuptake inhibitors such as fluvoxamine and fluoxetine⁵⁻⁹ have been added to neuroleptic treatment strategies on the assumption that negative symptoms might be associated with serotonergic dysfunction.^{10,11} We designed a pilot study to explore the efficacy of paroxetine as an add-on therapy to antipsychotics with respect to the treatment of negative symptoms in chronic schizophrenia. Patients were followed up for 30 months to ascertain the stability of any initial improvement.

Eight patients with chronic schizophrenia as defined by DSM-IV who scored at least 20 points on the negative subscale of the Positive and Negative Syndrome Scale (PANSS)¹² were treated with 30 mg/day of paroxetine in an open-label, non-blinded trial for 12 weeks and were followed up at 6, 12, 24, and 30 months. Ratings included the PANSS and measures of affective state (the Hamilton Rating Scale for Depression [HAM-D]¹³), extrapyramidal side effects, and paroxetine side effects. To exclude patients suffering from depression rather than negative symptoms of schizophrenia, a maximum score of 12 on the HAM-D was allowed. The previous neuroleptic treatment remained unchanged throughout the study period.

Of the 8 patients (5 male, 3 female; mean age = 40.5 years; range, 27–56 years) who entered the study, 2 were removed from the study due to noncompliance. The data of the remaining 6 were analyzed. The mean score on the negative subscale of the PANSS decreased significantly from 29.3 before treatment with paroxetine to 20.3 after 12 weeks of treatment ($p = .043$, Wilcoxon matched-pairs signed rank test). The effect was most pronounced concerning blunted affect and stereotyped thinking. The mean HAM-D score decreased from 8.17 to 4.5 ($p = .043$; no correlation with decrease in PANSS score [Spearman correlation = 0.52, $p = .29$]). No side effects occurred. One patient who had markedly improved during the 12 weeks discontinued paroxetine medication and experienced dramatic deterioration in condition, but improved again after restarting paroxetine and has remained on treatment with it since. One patient who did not benefit within the study period continued to take paroxetine and showed a substantial reduction from 31 to 21 points on the negative subscale of the PANSS after 16 weeks, maintaining that improvement for the following 30 months. The other 4 patients never changed medication and maintained their initial clinical improvement throughout the follow-up period; 2 even started to work again after many years of unemployment.

This study gives preliminary evidence of the sustained efficacy and tolerability of paroxetine with respect to the treatment of negative symptoms in chronic schizophrenia. To confirm those results, a larger, double-blind, placebo-controlled trial is needed.

REFERENCES

1. Davis JM, Schaffer CB, Killian GA, et al. Important issues in the drug treatment of schizophrenia. *Schizophr Bull* 1980;6:70–87
2. Kane J, Honigfeld G, Singer J, et al, and the Clozaril Collaborative Study Group. Clozapine for the treatment-resistant schizophrenic.

- Arch Gen Psychiatry 1988;45:789–796
3. Plasky P. Antidepressant usage in schizophrenia. *Schizophr Bull* 1991;17:649–657
4. Siris SG. Diagnosis of secondary depression in schizophrenia: implications for DSM-IV. *Schizophr Bull* 1991;17:75–97
5. Goldman MB, Janecek HM. Adjunctive fluoxetine improves global function in chronic schizophrenia. *J Neuropsychiatry* 1990;2:429–431
6. Goff DC, Brotman AW, Waites M, et al. Trial of fluoxetine added to neuroleptics for treatment-resistant schizophrenic patients. *Am J Psychiatry* 1990;147:492–494
7. Silver H, Nassar A. Fluvoxamine improves negative symptoms in treated chronic schizophrenia: an add-on double-blind, placebo-controlled study. *Biol Psychiatry* 1992;31:698–704
8. Goff DC, Midha KK, Sarid-Segal O, et al. A placebo-controlled trial of fluoxetine added to neuroleptic in patients with schizophrenia. *Psychopharmacology (Berl)* 1995;117:417–423
9. Buchanan RW, Kirkpatrick B, Bryant N, et al. Fluoxetine augmentation of clozapine treatment in patients with schizophrenia. *Am J Psychiatry* 1996;153:1625–1627
10. Oluoha DC, Hyde TM, Kleinman JE. The role of serotonin in schizophrenia: an overview of the nomenclature, distribution and alterations of serotonin receptors in the central nervous system. *Psychopharmacology (Berl)* 1993;112:S5–S15
11. Iqbal N, van Praag HM. The role of serotonin in schizophrenia. *Eur Neuropsychopharmacol* 1995;5(suppl):11–23
12. Kay SR, Opler LA, Lindenmayer J-P. The Positive and Negative Syndrome Scale (PANSS): rationale and standardisation. *Br J Psychiatry* 1989;155(suppl 7):59–65
13. Hamilton M. A rating scale for depression. *J Neurol Neurosurg Psychiatry* 1960;23:56–62

Maria C. Jockers-Scherübl, M.D.
Frank Godemann, M.D.
Adolf Pietzcker, M.D.
Free University of Berlin
Berlin, Germany

Pisa Syndrome Due to a Cholinesterase Inhibitor (Donepezil): A Case Report

Sir: Ekblom et al.¹ reported on 3 elderly women who exhibited tonic lateral flexion accompanied by slight rotation of the trunk that increased while they were walking. They considered this peculiar body posture to be a new type of dystonic reaction to antipsychotics and called it Pisa syndrome. Reports on the clinical characteristics of Pisa syndrome have been accumulating in the literature. Originally, the syndrome seemed to be exclusively a side effect of long-term neuroleptic medication. Although dopaminergic dysfunction has been implicated in this syndrome, the involvement of other neurotransmitters has also been suggested.² We report development of Pisa syndrome in a patient taking a novel cholinesterase-inhibiting, cognition-enhancing agent, donepezil.

Case report. Mr. A, a 57-year-old Japanese man, presented with a 2-year history of probable Alzheimer's disease as defined by National Institute of Neurological and Communicative Disorders and Stroke/Alzheimer's Disease and Related Disorders Association criteria.³ No one in his family had had dementia or any neurodegenerative disorder. Neuroradiological examinations, such as computed tomography and magnetic resonance imaging, revealed bilateral moderate cortical atrophy (predominantly in the frontotemporal lobe). He had never been exposed to psychotropic medications. Because of severe psychomotor agitation and memory dysfunction and a Mini-Mental State Examination⁴ score of 15/30, Mr. A was given 5 mg of donepezil daily. After this therapy was begun, psychosis and memory

dysfunction slowly improved. However, 4 weeks later, he was suddenly seen to be leaning backward and to the right side, a condition that worsened while he was walking. There were no other neurologic symptoms. He was diagnosed with Pisa syndrome (as defined using the criteria described by Ekbom et al.¹), and donepezil was quickly tapered off. Seven days after discontinuation of donepezil, all signs of dystonia had fully resolved. Ten weeks after cessation of donepezil, with permission of Mr. A and his wife, donepezil was resumed at 3 mg/day and gradually increased up to 5 mg/day for 3 weeks, at which time right axial dystonia was noted again. This symptom disappeared within 7 days after discontinuation of donepezil. The symptoms did not recur over the next several months.

The present case fits the description by Ekbom et al.¹ of Pisa syndrome, with flexion of the trunk to one side accompanied by slight rotation backward. No other extrapyramidal symptoms (e.g., parkinsonism, tardive dyskinesia, oculogyric crisis) were noted at the time of appearance of the syndrome. Earlier reports have suggested that Pisa syndrome generally develops in patients taking neuroleptic medications for prolonged periods and may often be associated with underlying brain lesions.^{1,5-7} However, in this case, neuroleptic medication had not been prescribed. In some previous reports, Pisa syndrome developed in patients with organic brain disorders and without neuroleptic exposure, confirming the earlier hypothesis that comorbidity with central nervous system disorders may increase the risk of Pisa syndrome.⁸⁻¹⁰ In the present case, cerebral cortical atrophy was also observed on neuroradiological examination. Pisa syndrome observed in our patient developed when the dose of donepezil was increased to 5 mg/day, and after discontinuation of donepezil, all signs of Pisa syndrome were fully resolved. Moreover, after initiation of donepezil again, the syndrome reappeared.

Although the pathophysiology of Pisa syndrome has not been established, previous cases of induction of the condition by neuroleptics and improvement with trihexyphenidyl suggest that dopaminergic-cholinergic imbalance was the main factor involved.^{5,11} Recently, Kwak et al.¹² reported a relationship between cholinesterase inhibitors and Pisa syndrome. Although their study had many features in common with our case, their patients were given neuroleptics. Our patient had never been exposed to neuroleptics. Therefore, theoretically, cholinergic excess could be another factor in Pisa syndrome, especially in cholinergically imbalanced individuals with Alzheimer's disease. A cholinesterase inhibitor alone could induce Pisa syndrome in Alzheimer's disease.

REFERENCES

1. Ekbom K, Lindholm H, Ljungberg L. New dystonic syndrome associated with butyrophenone therapy. *J Neurol* 1972;202:94-103
2. Remington GJ. The Pisa syndrome: possible role for serotonin and noradrenaline. *J Clin Psychopharmacol* 1988;8:228-229
3. McKham G, Drachman D, Folstein M, et al. Clinical diagnosis of Alzheimer's disease: report of the NINCDS-ADRDA work group under the auspices of the Department of Health and Human Services Task Force on Alzheimer's Disease. *Neurology* 1984;34:939-944
4. Folstein MF, Folstein SE, McHugh PR. Mini-Mental State: a practical method for grading the cognitive state of patients for the clinician. *J Psychiatr Res* 1975;12:189-198
5. Suzuki T, Koizumi J, Moroji T, et al. Clinical characteristics of the Pisa syndrome. *Acta Psychiatr Scand* 1990;82:454-457
6. Stübner S, Padberg F, Grohmann R, et al. Pisa syndrome (pleurothotonus): report of a multicenter drug safety surveillance project. *J Clin Psychiatry* 2000;61:569-574
7. Yassa R. The Pisa syndrome: a report of two cases. *Br J Psychiatry*

- 1985;146:93-95
8. Patel S, Tariot PN, Hamill RW. Pisa syndrome without neuroleptic exposure in a patient with dementia of the Alzheimer type. *J Geriatr Psychiatry Neurol* 1991;4:48-51
9. Tariot PN, Pendlebury W, Hamill R. Pisa syndrome without neuroleptic exposure in a patient with dementia of the Alzheimer type: a follow-up report [letter]. *J Geriatr Psychiatry Neurol* 1997;10:130
10. Colosimo C. Pisa syndrome in a patient with multiple system atrophy. *Mov Disord* 1998;13:607-609
11. Suzuki T, Hori T, Baba A, et al. Effectiveness of anticholinergics and neuroleptic dose reduction on neuroleptic-induced pleurothotonus (the Pisa Syndrome). *J Clin Psychopharmacol* 1999;19:277-280
12. Kwak YT, Han IW, Baik J, et al. Relation between cholinesterase inhibitor and Pisa syndrome [letter]. *Lancet* 2000;355:2222

Tsuyoshi Miyaoka, M.D.
Haruo Seno, M.D.
Chikako Yamamori, M.D.
Takuji Inagaki, M.D.
Motoi Itoga, M.D.
Ken Tsubouchi, M.D.
Jun Horiguchi, M.D.
Shimane Medical University
Izumo, Japan

Bipolar Affective Disorder and Idiopathic Pulmonary Fibrosis

Sir: The genetic etiology of bipolar affective disorder is well established.¹ Recent genetic linkage studies have implicated several bipolar susceptibility loci, but the results remain inconclusive.² One of the strategies used to identify genes of interest is to look for the cosegregation of certain diseases with affective disorder.³ We report a case of bipolar disorder associated with idiopathic pulmonary fibrosis (also known as cryptogenic fibrosing alveolitis), a rare respiratory disorder with a prevalence of 5 to 10 per 100,000 in the general population.⁴ Genetic factors are considered important in its etiology, the strongest evidence being provided by familial cases.⁵ A previous association has been reported.⁶

Case report. Ms. A, a 60-year-old mother of 2, was first admitted at the age of 29 years with a history of severe depression requiring treatment with electroconvulsive therapy. Subsequently, she suffered from episodes of both depression and mania, requiring hospitalized treatment. In 1985, she was prescribed lithium, and she remained well apart from mild depressive episodes until 1997, after which the severity of her illness worsened. She has no known family history of mental illness or pulmonary fibrosis.

In 1994, she was diagnosed with idiopathic pulmonary fibrosis on the basis of computed tomography scan, transbronchial biopsy, and bronchial alveolar lavage. She was treated with oral corticosteroids for a short while, but no clear worsening of her mental state was noticed. Her autoantibody screen was negative apart from a nonsignificant presence of antithyroid peroxidase antibodies.

In this case, the diagnosis of bipolar I disorder (DSM-IV) is clear, as she had episodes of both mania and depression. The manic episode occurred prior to her diagnosis of idiopathic pulmonary fibrosis and was unrelated to the use of steroids.

An association between bipolar affective disorder and idiopathic pulmonary fibrosis is a very interesting one, since genetic factors are considered to be important in the etiology of

both conditions. Three previous cases have been reported in the literature.⁶ The present case differs from the previous ones reported, since the 2 disorders cosegregated in the same family in 1 of the 3 cases, and there was a family history of mental illness in another. In addition, other autoimmune disorders and autoantibodies were present in those 3 cases.

Once genetic linkage is established, it could serve as a region of interest for either illness. One study has suggested the possibility of linkage of idiopathic pulmonary fibrosis to chromosome 14.⁷ Another important association is that of autoimmunity, because non-organ-specific autoantibodies are found in 45% of idiopathic pulmonary fibrosis cases.⁸ Bipolar affective disorder has been reported in association with disorders such as Crohn's disease as well as diabetes mellitus, in which an autoimmune etiology is suspected.^{9,10} In addition, autoimmune factors play a very important role in the occurrence of hypothyroidism¹¹ and hyperthyroidism¹² related to lithium, most commonly used in bipolar affective disorder, suggesting that both of these disorders may be linked to the underlying affective disorder. These findings indicate that there is a possibility that the co-occurrence of idiopathic pulmonary fibrosis and bipolar affective disorder may relate to the fact that bipolar affective disorder often co-occurs with certain autoimmune disorders.

In conclusion, this case report, along with the 3 previous cases,⁶ represents an interesting association that is worthy of further study, which perhaps could lead to a better understanding of both disorders.

REFERENCES

1. McGuffin P, Sargant M. Genetic markers and affective disorder. In: McGuffin P, Murray R, eds. *The New Genetics of Mental Illness*. Oxford, England: Butterworth-Heinemann; 1991:165-181

2. Gershon ES. Bipolar illness and schizophrenia as oligogenic diseases: implications for the future. *Biol Psychiatry* 2000;47:240-244
3. Craddock N, Owen M, Burge S, et al. Familial cosegregation of major affective disorder and Darier's disease. *Br J Psychiatry* 1994;164:355-358
4. Crystal RG, Bitterman PB, Renaud SI, et al. Interstitial lung diseases of unknown cause, pt 1. *N Engl J Med* 1984;310:154-166
5. Marshall RP, Puddicombe A, Cookson WO, et al. Adult familial cryptogenic fibrosing alveolitis in the United Kingdom. *Thorax* 2000;55:143-146
6. Bhandari S. Bipolar affective disorder and autoimmune disease. *Irish J Psychol Med* 1996;13:77-78
7. Musk AW, Zilko PJ, Manners P, et al. Genetic studies in familial fibrosing alveolitis: possible linkage with immunoglobulin allotypes (Gm). *Chest* 1986;89:207-210
8. Du Bois RM. Cryptogenic fibrosing alveolitis. In: Weatherall DJ, Ledingham JCG, Warrell DA, eds. *Oxford Textbook of Medicine*. Oxford, England: Oxford University Press; 1996:2786-2795
9. Holroyd S, DePaulo JR Jr. Bipolar disorder and Crohn's disease. *J Clin Psychiatry* 1990;51:407-409
10. Cassidy F, Ahearn E, Carroll BJ. Elevated frequency of diabetes mellitus in hospitalized manic-depressive patients. *Am J Psychiatry* 1999;156:1417-1420
11. Lazarus JH, McGregor AM, Ludgate M, et al. Effect of lithium carbonate on thyroid immune status in manic depressive patients: a prospective study. *J Affect Disord* 1986;11:155-160
12. McDermott M, Burman K, Hofeldt K, et al. Lithium associated thyrotoxicosis. *Am J Med* 1986;80:1245-1248

Sadgun Bhandari, M.D.
 East Ham Memorial Hospital
Dimitri Samellas, M.D.
 St. Clement's Hospital
 London, England