

More on Placebo Response

Sir: The article by Stein et al.¹ on placebo response may, due to the data available, be missing much of the “forest” in the United States. Larger issues include the following:

1. There are many fewer untreated depressed patients in the community today than even 5 to 10 years ago, thanks to reduced stigma regarding depression, widespread prescribing by family practitioners and other physicians of the newer antidepressants (which are so relatively safe and easy to use), and the low cost of generic antidepressants. In my first drug company–funded depression study,² I easily recruited 45 patients, spending less than \$5000 on newspaper ads. Currently, \$5000 for ads near Princeton might yield 2 or 3 patients.
2. In the “old days,” studies typically involved fewer investigators, with each investigator entering more patients. With the considerable (and increasing) time required to prepare for a study (e.g., being certified on ratings), a study is not really worth doing if one can enter only a few patients. By the time investigators have prepared their staff to conduct a study, they are strongly motivated to enter as many patients as possible quickly, especially with competitive enrollment and the prospect of a study ending early if other sites recruit quickly. Advertising funds are also often limited. A recent study (J.A.M., unpublished data, 2002–2003) had a high placebo response rate and increased recruitment later in the study when it seemed that some of the sites were not going to have time enough to recruit the originally requested number of patients; drug-placebo differences were less in the group of patients that was entered at this time, presumably due to excessive investigator motivation to enter patients quickly. Rather than the many machinations companies have gone through to try to minimize placebo response, such as increased training and blinded raters, I believe that a more productive approach would be to have fewer sites, to guarantee sites that they would have a certain number of months to enter the requested number of patients without worrying that the study would end earlier, and to have a very liberal advertising budget once the sites have been selected. In addition, exclusion criteria in protocols are sometimes excessive, unnecessarily excluding patients who are ideal from other perspectives (e.g., a patient with prior depressive episodes who has responded well to medications).

One approach, if approved by institutional review boards, would be to pay patients who are known to be medication responsive (and who are on maintenance antidepressants) to discontinue medication, become depressed, and participate in a study. Even at \$10,000 per patient, drug companies would be ahead financially; a much smaller N would be needed, using this ideal population. The ethics may be reasonable (for non-suicidal patients), especially given the peculiar (and relatively recent) belief that it is unethical for corporations to focus on anything other than shareholder profit. Why shouldn't depressed, medication-responsive patients, who can reliably demonstrate and discern a medication effect, also profit?

Dr. Mattes reports no financial affiliation or other relationship relevant to the subject of this letter.

REFERENCES

1. Stein DJ, Baldwin DS, Dolberg OT, et al. Which factors predict placebo response in anxiety disorders and major depression? an analysis of placebo-controlled studies of escitalopram. *J Clin Psychiatry* 2006;67:1741–1746
2. Roth D, Mattes JA, Sheehan KH, et al. A double-blind comparison of fluvoxamine, desipramine, and placebo in outpatients with depression. *Prog Neuropsychopharmacol Biol Psychiatry* 1990;2:929–939

Jeffrey Allan Mattes, M.D.

Psychopharmacology Research Association of Princeton
Princeton, New Jersey

Dr. Stein and Colleagues Reply

Sir: We are pleased that our article¹ on the placebo response in the escitalopram randomized controlled trials has generated some discussion.

Dr. Mattes's first point is that there are fewer untreated depressed patients in the community than there used to be. Epidemiologic data certainly indicate that over the past decade or more, there has been an increase in treatment rate in patients with a mental disorder in the United States.² Nevertheless, we would also note another conclusion from such work: most patients with a mental disorder do not receive treatment.²

In his second point, Dr. Mattes suggests that pressure to recruit may result in an increased placebo response rate and that addressing this issue (e.g., with noncompetitive recruitment and better advertising budgets) is more useful than other approaches focused on reducing the placebo response (e.g., more training and use of “blinded” raters). Certainly, multiple factors affect the placebo response. Nevertheless, our view is that different approaches need to be taken to maximize medication-placebo differences and that the data about which methods are best are not yet conclusive.¹

Finally, Dr. Mattes suggests that depressed patients who previously responded to medication and are on maintenance treatment should be allowed to relapse and be paid to participate in clinical trials sponsored by the pharmaceutical industry. This proposal strikes us as unethical (patients would effectively be paid to become ill), and we are not convinced the data would be meaningful (payment may result in distortion of symptoms, and the sample is unlikely to be a representative one).

We take the opportunity of a discussion about recruitment into clinical trials to reiterate a point made by Chalmers and Lindley³ that there is a need to increase awareness of the “inclusion benefit” for participants in clinical trials. Many conceptualize trial participants as being “human guinea pigs.” In fact, routine clinical care is often experimental, and treatment in the context of a trial can have excellent outcomes. Indeed, a systematic review of studies comparing patients treated in the context of controlled trials with apparently similar patients treated outside trials showed that, on average, the prognoses of the former are better than those of the latter.³

The study referred to in this letter was supported by H. Lundbeck A/S. Dr. Stein has received research grants and/or consultancy honoraria from AstraZeneca, Eli Lilly, GlaxoSmithKline, Lundbeck, Orion, Pfizer, Pharmacia, Roche, Servier, Solvay, Sumitomo, and Wyeth. Dr. Baldwin has been a consultant for Asahi, Cephalon, Eli Lilly, GlaxoSmithKline, Lundbeck, Organon, Pfizer, Pharmacia, Pierre Fabre, Roche, Servier, and Wyeth; has received grant/research support from Cephalon, Eli Lilly, GlaxoSmithKline, Lundbeck, Organon, Pfizer, Roche, and Wyeth; has received honoraria from Cephalon, Eli Lilly, GlaxoSmithKline, Lundbeck,

Pfizer, and Wyeth; and has served on the speakers or advisory boards for Eli Lilly, GlaxoSmithKline, Lundbeck, and Pierre Fabre. Dr. Dolberg and Mr. Despiegel are employees of H. Lundbeck A/S. Dr. Bandelow has been a consultant for AstraZeneca, Cephalon, Lundbeck, Pfizer, Roche, and Wyeth and has served on the speakers or advisory boards for AstraZeneca, Bristol-Myers Squibb, Dainippon Sumitomo, Janssen, Eli Lilly, Lundbeck, Sanofi-Aventis, Pfizer, and Xian-Janssen.

REFERENCES

1. Stein DJ, Baldwin DS, Dolberg OT, et al. Which factors predict placebo response in anxiety disorders and major depression? an analysis of placebo-controlled studies of escitalopram. *J Clin Psychiatry* 2006;67:1741–1746
2. Kessler RC, Demler O, Frank RG, et al. Prevalence and treatment of mental disorders, 1990 to 2003. *N Engl J Med* 2005;352:2515–2523
3. Chalmers I, Lindley R. Double standards on informed consent to treatment. In: Doyal L, Tobias JS, eds. *Informed Consent in Medical Research*. London, England: BMJ Publications; 2001:266–275

Dan J. Stein, M.D., Ph.D.

Department of Psychiatry
University of Cape Town
Cape Town, South Africa
David S. Baldwin, M.D.

Clinical Neuroscience Division, School of Medicine
University of Southampton
Southampton, United Kingdom

Ornah T. Dolberg, M.D.

Nicolas Despiegel, M.Sc.

H. Lundbeck A/S

Copenhagen, Denmark

Borwin Bandelow, M.D.

Department of Psychiatry and Psychotherapy
University of Göttingen
Göttingen, Germany

Corpus Callosum Dysplasia in Adult Attention-Deficit/Hyperactivity Disorder: A Case Report

Sir: Primary attention-deficit/hyperactivity disorder (ADHD) is generally believed to be a disorder of adrenergic and dopaminergic neurotransmission, but there are also secondary forms of ADHD, for example, in patients with epilepsy or Tourette's disorder.

We report on an adult patient who presented with classical primary ADHD symptoms that began in early childhood in association with moderate dyslexia. Treatment with psychostimulant medication did not yield positive effects, and even worsened the patient's impulsivity and irritability. Routine magnetic resonance imaging (MRI) scanning mainly showed a severe form of partial agenesis and dysplasia of the corpus callosum. Electroencephalogram (EEG) and laboratory examination findings were essentially within normal limits.

This is the first published report of an association between agenesis of the corpus callosum and adult ADHD. There are, however, publications on this association in children.^{19–21} Clinicians should be aware of this association because afflicted patients might not respond or even respond adversely to psychostimulant medication. This case illustrates the need for thorough investigations of ADHD patients, including brain imaging. We discuss the possible role of the corpus callosum in the pathogenesis of ADHD and therapeutic implications.

ADHD is defined as the continuous presence of certain core symptoms beginning in early childhood.¹ While hyperactivity

often fades away during adolescence, other core symptoms such as attention deficit, impulsivity, and emotional instability often persist in adulthood and cause many problems in occupational, interpersonal, and social life.

The etiology of ADHD is still poorly understood. The primary form of ADHD has a high genetic loading with a positive family history.^{2,3} However, there are also secondary forms of ADHD in the context of other neuropsychiatric disorders such as epilepsy,⁴ chorea minor (Sydenham's chorea),⁵ or Gilles de la Tourette disorder.^{6,7}

Particularly in primary ADHD, there is much evidence that suggests a crucial pathogenic role of systemic adrenergic and dopaminergic dysfunctions (for review, see references 8 and 9). Imaging studies support the hypothesis that this central pathophysiology during development leads to morphometric and functional brain abnormalities that correlate with the neuropsychological and psychiatric symptoms of ADHD.^{8,10,11} The brain regions that are most commonly viewed as abnormal in ADHD include the prefrontal lobe, the basal ganglia, and the cerebellum, and there is also growing evidence of corpus callosum abnormalities.¹²

We present a case of an adult patient with classical symptoms of ADHD and moderate dyslexia who suffers from a severe form of partial agenesis and dysplasia of the corpus callosum.

Case report. Mr. A, a 32-year-old white male construction worker, presented to our ADHD outpatient clinic in 2005 complaining about symptoms of motor hyperactivity and inner agitation, severe inattention, extreme impulsivity (e.g., throwing objects around due to anger), and emotional instability since childhood.

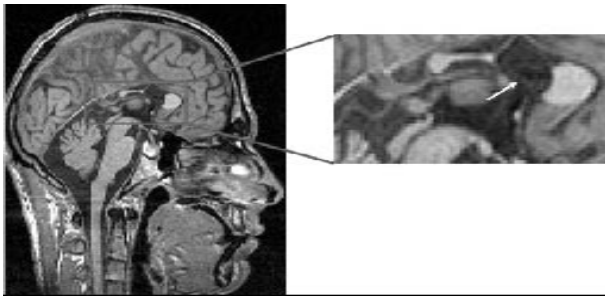
His school reports reflected this history and were confirmed by his mother. The patient was diagnosed with moderate dyslexia in the fourth grade. The mother recalled a long and difficult delivery; however, no birth complications were documented. Also, there was no history of other organic brain disease due to pregnancy complications, and there were no infective or inflammatory brain diseases or childhood seizures. Moreover, neither his 2 siblings nor other relatives of first or second degree had ADHD symptoms, dyslexia, or other neuropsychiatric disorders.

The clinical diagnosis of persisting adult ADHD was made based on careful psychiatric and psychometric investigations using the short version of the Wender Utah Rating Scale¹³ (WURS-k; German version¹⁴), which includes 25 items scored on a 5-point Likert scale (0–4, “not at all” to “severe”). Additionally, we used the ADHD-Checklist (ADHD-CL),¹⁵ which includes 18 items scored on a 3-point Likert-scale corresponding to the diagnostic criteria of DSM-IV (0–2, “not at all” to “severe”). His WURS-k score was 66, and his ADHD-CL score was 24. Also, histories were taken from relatives and caregivers. Findings of other routine medical, EEG, and laboratory investigations were essentially within normal limits (slightly decreased white blood cells: 3500/μL; normal range = 4300–10,000/μL). The patient's neurologic examination indicated no focal deficits.

The patient had not been previously treated with any medication. His parents had merely sought educational advice. Therefore, we prescribed methylphenidate, a first-line medication. Taking into consideration its effects and adverse events, we carefully titrated it to 1.0 mg/kg (65 mg daily) for 12 weeks. This resulted in slight gastrointestinal side effects but no clinical benefit. On the contrary, impulsivity and irritability even worsened as reported by the patient, his family members, and his partner.

A T1-weighted MRI study that was primarily performed for research purposes revealed a severe form of dysplasia of the

Figure 1. Magnetic Resonance Image Showing Severe Partial Agenesis and Dysplasia of the Corpus Callosum^a



^aArrow indicates circular cystic structure of the pituitary gland, which was radiologically assessed as a likely hemorrhage or protein-rich cyst.

corpus callosum in combination with a cystic abnormality in the area of the pituitary gland. Subsequent elaborated T1- and T2-weighted MRI studies confirmed the radiological diagnosis of agenesis and dysplasia of the corpus callosum with a cystic alteration of the anterior splenium and hypoplasia of the posterior splenium (see Figure 1). Only the anterior portion of the cingulate gyrus was present, and the circular cystic structure of the pituitary gland was radiologically assessed as a hemorrhage or a protein-rich cyst. There was no evidence of inflammation or proliferating abnormalities in that area.

Subsequent extensive neuroendocrinological studies showed essentially normal findings (findings were within normal limits for thyroid-stimulating hormone, luteinizing hormone, follicle-stimulating hormone, testosterone, prolactin, insulin-like growth factor, dehydroepiandrosterone, slightly increased adrenocorticotrophic hormone [ACTH, 70 pg/mL; normal range, 9–52 pg/mL], and cortisol [624 nmol/L; normal range, 171–536 nmol/L]). The slightly increased concentrations of ACTH and cortisol were assessed to be noncritical by our endocrinological experts. A follow-up MRI 6 months later revealed no structural difference compared to the baseline MRI. The patient refused to take any other medication, but did receive psychiatric therapy including behavioral therapy.

In summary, this is the first published case of an adult patient with clinical presentation of classical ADHD and moderate dyslexia along with a severe partial agenesis and dysplasia of the corpus callosum in association with a cystic lesion in the pituitary and an abnormality of the posterior cingulate. Since the slightly elevated concentrations of ACTH and cortisol were assessed to be noncritical by our endocrinological experts, the agenesis and dysplasia of the corpus callosum and the posterior cingulate are the prevailing pathologic brain findings in this patient. However, we cannot exclude that, in spite of essentially normal functional parameters of the pituitary gland, dysfunction of this neuroendocrinological system possibly linked to the cystic lesion might play a role in the pathogenesis of the ADHD symptoms in this patient. Nevertheless, for the reasons mentioned in the discussion that follows, we want to concentrate on the possible pathogenetic role of the corpus callosum and the posterior cingulate in this patient.

The corpus callosum is the major commissure connecting the cerebral hemispheres. In ADHD, the corpus callosum—particularly the splenium—is one of the regions most frequently reported as abnormally reduced in volume.^{12,16,17}

In animal models, an association between total agenesis of the corpus callosum and ADHD-like symptoms has been reported.¹⁸ However, we found few cases of children with total or partial agenesis of the corpus callosum associated with ADHD. An early (1980) study¹⁹ describes the case of a girl with agenesis of the corpus callosum and “minimal brain dysfunction,” a concept used to describe ADHD at that time, as well as mild dyslexia. Parraga and coworkers²⁰ also reported 2 cases of patients with attention deficits associated with other psychiatric and behavioral problems: 1 boy with total agenesis and colpocephaly (abnormal enlargement of the occipital horns) and 1 girl with partial agenesis of the corpus callosum, predominantly of the rostrum and the body. The boy with the total agenesis of the corpus callosum also suffered from complex partial seizures; the girl showed slightly abnormal EEG findings. There is also 1 case report of a boy with classical ADHD and oppositional defiant disorder in whom MRI revealed a total agenesis of the corpus callosum.²¹ In that case, medical treatment with methylphenidate brought about improvement of the attentional problems, whereas the impulse-control disturbance remained unchanged. The latter did decrease with behavioral treatment and neuroleptic medication with sulpiride.

The question arises whether our case should be nosologically classified as a form of primary ADHD and moderate dyslexia with additional incidental brain abnormalities, or alternatively as a secondary form of ADHD due to partial agenesis and dysplasia of the corpus callosum (i.e., as a kind of organic psychiatric disorder). In addition to genetic factors, low birth weight (< 2500 g), premature birth, and complications during pregnancy and neonatal life have been identified as risk factors for ADHD.⁹ Interestingly, in very low-birth-weight adolescents (< 1500 g), a thinning and white matter reduction of the corpus callosum was also found and was associated with severity of ADHD symptoms.²² In this context, it is striking that a large follow-up study in young children with prenatally diagnosed agenesis of the corpus callosum revealed persisting attention problems and irritability despite essentially normal cognitive functioning.²³

Besides the potential role of the corpus callosum in the pathogenesis of ADHD symptomatology, the lesion of the cingulate cortex must be considered. In ADHD, there are several reports of volume reductions²⁴ and altered functions of the anterior cingulate cortex²⁵ as well as of its involvement in medical effects of methylphenidate.^{26,27} In our case, however, the posterior portion was absent. The posterior cingulate receives afferents from the thalamus and the hippocampus. However, little is known about a specific role of the posterior cingulate in ADHD symptomatology. One study²⁸ revealed abnormal morphometric findings of the left posterior cingulate associated with volume decrease of the anterior and middle cingulate cortex in children and adolescents with ADHD, suggesting that the posterior cingulate may also play a potential role in the pathogenesis of ADHD, particularly in emotional processing, which has been reported in anxiety disorders²⁹ and schizophrenia.³⁰ With regard to the co-occurring dyslexia, it is interesting that in patients with traumatic brain injuries a dysfunction of the posterior cingulate was associated with an impairment of learning and memory.³¹ Nevertheless, the precise function of the posterior cingulate is still poorly understood.

There are a few points in the history and the clinical course of this case that might have hinted at an organic or secondary form of ADHD. First, there was no positive family history. Second, though the patient also complained about dyslexia, which is often combined with ADHD,³² and though both disorders might be explained, at least in part, by genetic factors,³³ dyslexia in the context of ADHD might still be an indicator of a

secondary pathogenesis possibly pointing to a more widespread brain pathology in terms of corticocortical disconnectivity and dysfunction of the corpus callosum. This hypothesis is supported by the fact that severe corpus callosum volume reduction has been associated with dyslexia.^{34–39} Third, in a recently published large survey, persons with agenesis of the corpus callosum had a greater risk for neurologic deficits and different behavioral problems compared to their siblings.⁴⁰

Finally, the patient did not benefit from stimulant treatment. In contrast, the symptoms even worsened. This finding is in line with one study that revealed smaller splenium areas of the corpus callosum in children with ADHD who did not respond well to stimulants compared to stimulant responders.³⁴

It has been found that children with ADHD have disturbed transcallosally mediated inhibition. This finding indicates a probable dysbalance between excitatory and inhibitory inter-neuronal activities,^{41,42} which could be improved after medication with methylphenidate.⁴² Thus, the corpus callosum might be an important target structure of methylphenidate effects.

In summary, we feel that our patient should be classified as suffering from a secondary form of ADHD in spite of the classical psychopathologic presentation. The case highlights several important clinical points. First, it illustrates the need for thorough baseline diagnostics. Routine MRI or computed tomography scans are currently not recommended in many countries.⁴³ However, at least in those cases with insufficient response to medical treatment or with unusual adverse events, further cerebral imaging studies should be performed. Second, this case supports the hypothesis that dyslexia in the context of ADHD symptoms might hint at a secondary pathogenesis such as cortical disconnectivity and corpus callosum dysfunction. Finally, clinicians should be aware of this malformation because it might predict poor or even adverse response to psychostimulant treatment in ADHD.

The study was conducted without any intramural financial support.

The authors report no financial affiliation or other relationship relevant to the subject of this letter.

REFERENCES

- Faraone SV, Biederman J, Mick E. The age-dependent decline of attention deficit hyperactivity disorder: a meta-analysis of follow-up studies. *Psychol Med* 2006;36:159–165
- Li D, Sham PC, Owen MJ, et al. Meta-analysis shows significant association between dopamine system genes and attention deficit hyperactivity disorder (ADHD). *Hum Mol Genet* 2006;15:2276–2284
- Bobb AJ, Castellanos FX, Addington AM, et al. Molecular genetic studies of ADHD: 1991 to 2004. *Am J Med Genet B Neuropsychiatr Genet* 2005;132:109–125
- Dunn DW, Kronenberger WG. Childhood epilepsy, attention problems, and ADHD: review and practical considerations. *Semin Pediatr Neurol* 2005;12:222–228
- Maia DP, Teixeira AL Jr, Quintao Cunningham MC, et al. Obsessive compulsive behavior, hyperactivity, and attention deficit disorder in Sydenham chorea. *Neurology* 2005;64:1799–1801
- Baumgardner TL, Singer HS, Denckla MB, et al. Corpus callosum morphology in children with Tourette syndrome and attention deficit hyperactivity disorder. *Neurology* 1996;47:477–482
- Gaze C, Kepley HO, Walkup JT. Co-occurring psychiatric disorders in children and adolescents with Tourette syndrome. *J Child Neurol* 2006;21:657–664
- Biederman J. Attention-deficit/hyperactivity disorder: a selective overview. *Biol Psychiatry* 2005;57:1215–1220
- Sasaluxnanon C, Kaewpornsawan T. Risk factor of birth weight below 2,500 grams and attention deficit hyperactivity disorder in Thai children. *J Med Assoc Thai* 2005;88:1514–1518
- Bush G, Valera EM, Seidman LJ. Functional neuroimaging of attention-deficit/hyperactivity disorder: a review and suggested future directions. *Biol Psychiatry* 2005;57:1273–1284
- Seidman LJ, Valera EM, Makris N. Structural brain imaging of attention-deficit/hyperactivity disorder. *Biol Psychiatry* 2005;57:1263–1272
- Valera EM, Faraone SV, Murray KE, et al. Meta-analysis of structural imaging findings in attention-deficit/hyperactivity disorder. *Biol Psychiatry* 2006 Aug 31 [epub ahead of print]
- Ward MF, Wender PH, Reimherr FW. The Wender Utah Rating Scale: an aid in the retrospective diagnosis of childhood attention deficit hyperactivity disorder. *Am J Psychiatry* 1993;150:885–890
- Retz-Junginger P, Retz W, Blocher D, et al. Wender Utah Rating Scale. The short-version for the assessment of the attention-deficit hyperactivity disorder in adults [in German]. *Nervenarzt* 2002;73:830–838
- Rosler M, Retz W, Retz-Junginger P, et al. Tools for the diagnosis of attention-deficit/hyperactivity disorder in adults: self-rating behaviour questionnaire and diagnostic checklist [in German]. *Nervenarzt* 2004;75:888–895
- Krain AL, Castellanos FX. Brain development and ADHD. *Clin Psychol Rev* 2006;26:433–444
- Giedd JN, Castellanos FX, Casey BJ, et al. Quantitative morphology of the corpus callosum in attention deficit hyperactivity disorder. *Am J Psychiatry* 1994;151:665–669
- Magara F, Ricceri L, Wolfer DP, et al. The acallosal mouse strain I/LnJ: a putative model of ADHD? *Neurosci Biobehav Rev* 2000;24:45–50
- Thompson JS, Ross RJ, Horwitz SJ. The role of computed axial tomography in the study of the child with minimal brain dysfunction. *J Learn Disabil* 1980;13:334–337
- Parraga HC, Parraga MI, Jensen AR. Cognitive, behavioral, and psychiatric symptoms in two children with agenesis of the corpus callosum: case report. *Int J Psychiatry Med* 2003;33:107–113
- Roessner V, Banaschewski T, Uebel H, et al. Neuronal network models of ADHD—lateralization with respect to interhemispheric connectivity reconsidered. *Eur Child Adolesc Psychiatry* 2004;13 (suppl 1):171–179
- Indredavik MS, Skranes JS, Vik T, et al. Low-birth-weight adolescents: psychiatric symptoms and cerebral MRI abnormalities. *Pediatr Neurol* 2005;33:259–266
- Moutard ML, Kieffer V, Feingold J, et al. Agenesis of corpus callosum: prenatal diagnosis and prognosis. *Childs Nerv Syst* 2003;19:471–476
- Seidman LJ, Valera EM, Makris N, et al. Dorsolateral prefrontal and anterior cingulate cortex volumetric abnormalities in adults with attention-deficit/hyperactivity disorder identified by magnetic resonance imaging. *Biol Psychiatry* 2006;60:1071–1080
- Perlov E, Philipson A, Hesslinger B, et al. Reduced cingulate glutamate/glutamine-to-creatine ratios in adult patients with attention deficit/hyperactivity disorder—a magnet resonance spectroscopy study. *J Psychiatry Res* 2007 Feb 13 [epub ahead of print]
- Cho SC, Hwang JW, Kim BN, et al. The relationship between regional cerebral blood flow and response to methylphenidate in children with attention-deficit hyperactivity disorder: comparison between non-responders to methylphenidate and responders. *J Psychiatry Res* 2007;41:459–465
- Semrud-Clikeman M, Pliszka SR, Lancaster J, et al. Volumetric MRI differences in treatment-naïve vs chronically treated children with ADHD. *Neurology* 2006;67:1023–1027
- Carmona S, Vilarroya O, Bielsa A, et al. Global and regional gray matter reductions in ADHD: a voxel-based morphometric study. *Neurosci Lett* 2005;389:88–93
- Zhao XH, Wang PJ, Li CB, et al. Altered default mode network activity in patient with anxiety disorders: an fMRI study. *Eur J Radiol* 2007 Mar 30 [epub ahead of print]
- Zhou Y, Liang M, Jiang T, et al. Functional dysconnectivity of the dorsolateral prefrontal cortex in first-episode schizophrenia using resting-state fMRI. *Neurosci Lett* 2007;417:297–302
- Salmund CH, Menon DK, Chatfield DA, et al. Diffusion tensor imaging in chronic head injury survivors: correlations with learning and memory indices. *Neuroimage* 2006;29:117–124
- Willcutt EG, Pennington BF. Comorbidity of reading disability and attention-deficit/hyperactivity disorder: differences by gender and subtype. *J Learn Disabil* 2000;33:179–191

33. Bates TC, Luciano M, Castles A, et al. Replication of reported linkages for dyslexia and spelling and suggestive evidence for novel regions on chromosomes 4 and 17. *Eur J Hum Genet* 2007;15:194–203
34. Semrud-Clikeman M, Filipek PA, Biederman J, et al. Attention-deficit hyperactivity disorder: magnetic resonance imaging morphometric analysis of the corpus callosum. *J Am Acad Child Adolesc Psychiatry* 1994;33:875–881
35. von Plessen K, Lundervold A, Duta N, et al. Less developed corpus callosum in dyslexic subjects—a structural MRI study. *Neuropsychologia* 2002;40:1035–1044
36. Robichon F, Bouchard P, Demonet J, et al. Developmental dyslexia: re-evaluation of the corpus callosum in male adults. *Eur Neurol* 2000;43:233–237
37. Rumsey JM, Casanova M, Mannheim GB, et al. Corpus callosum morphology, as measured with MRI, in dyslexic men. *Biol Psychiatry* 1996;39:769–775
38. Hynd GW, Hall J, Novey ES, et al. Dyslexia and corpus callosum morphology. *Arch Neurol* 1995;52:32–38
39. Njokiktjien C, de Sonneville L, Vaal J. Callosal size in children with learning disabilities. *Behav Brain Res* 1994;64:213–218
40. Doherty D, Tu S, Schilmoeller K, et al. Health-related issues in individuals with agenesis of the corpus callosum. *Child Care Health Dev* 2006;32:333–342
41. Buchmann J, Wolters A, Haessler F, et al. Disturbed transcallosally mediated motor inhibition in children with attention deficit hyperactivity disorder (ADHD). *Clin Neurophysiol* 2003;114:2036–2042
42. Buchmann J, Gierow W, Weber S, et al. Modulation of transcallosally mediated motor inhibition in children with attention deficit hyperactivity disorder (ADHD) by medication with methylphenidate (MPH). *Neurosci Lett* 2006;405:14–18
43. Ebert D, Krause J, Roth-Sackenheim C, et al. ADHD in adulthood—guidelines based on expert consensus with DGPPN support [in German]. *Nervenarzt* 2003;74:939–946

Alexandra Philipsen, M.D.
Ludger Tebartz van Elst, M.D.
Evgeniy Perlov, M.D.
Dieter Ebert, M.D.
Bernd Hesslinger, M.D.

ADHD Research Group & Section for Experimental
 Neuropsychiatry
 Department of Psychiatry and Psychotherapy
 University Clinic of Freiburg
 Freiburg, Germany

Treatment of Cognitive Deficits in Schizophrenia With Atomoxetine: A Case Report

Sir: Schizophrenia patients have deficits in attention, concentration, and information processing that result in significant functional impairment.¹ Atomoxetine, a novel cognitive enhancer that can reduce executive function deficits,² has been postulated to potentially treat these deficits in schizophrenia.³ We report a patient with schizophrenia whose cognitive functioning improved after adjunctive treatment with atomoxetine.

Case report. Ms. A, a 36-year-old woman with a diagnosis of paranoid schizophrenia (DSM-IV), presented in 2006 with complaints of significant disturbances in attention and concentration leading to substantial occupational dysfunction, inability to follow lengthy conversations, and difficulties in other activities of daily living. Her psychotic symptoms had been well controlled with risperidone (2 mg/day) over the previous 5 years. On examination, Ms. A had no delusions or hallucinations and was euthymic, and her judgment and abstraction were intact. Results of liver and thyroid function tests were within normal limits. Neuropsychological assessments revealed significant

impairment in executive functions. Ms. A performed poorly on tests for executive functions, namely, the Trail-Making test parts A and B and the Stroop color-word interference test (Trail-Making test part A = 86 seconds and part B = 240 seconds, with 14 cognitive set-learning errors; Stroop interference score = 187 seconds and difference score = 121 seconds).

Since Ms. A did not have attention and concentration deficits before the onset of schizophrenia, the possibility of attention deficit disorder was ruled out and these deficits were diagnosed as part of cognitive deterioration in schizophrenia. She was started on atomoxetine, 18 mg/day; risperidone treatment was also continued. Repeat assessments using the same tests revealed substantial improvement in performance after 5 days (Stroop interference score = 100 seconds and difference score = 36 seconds; Trail-Making test part A = 70 seconds and part B = 143 seconds, with 5 cognitive set-learning errors).

During follow-up after 1 year, at which time she was still receiving atomoxetine and risperidone, Ms. A continued to exhibit no psychotic symptoms. She reported slight reduction in appetite but no other side effects. The improvements in cognitive deficits persisted, and she had become independent in her activities of daily living and could keep track of lengthy conversations. Also, she was employed as a computer operator with improved occupational functioning. These improvements were ascertained by reliable corroborative information obtained from 2 adult first-degree relatives.

To the best of our knowledge, this is the first report of reduction in cognitive deficits in schizophrenia after treatment with atomoxetine. Though the rapidity of improvement might suggest the possibility of a placebo effect, such an effect is unlikely because (1) in an earlier study examining attention-deficit/hyperactivity disorder, atomoxetine (18 mg/day) significantly reduced attention deficits as early as within 1 week⁴ and (2) persistent functional improvements were seen at 1-year follow-up (a placebo effect is less likely to persist⁵).

Atomoxetine, though it is a norepinephrine reuptake inhibitor, increases extracellular dopamine concentration in prefrontal cortex without any such effect in striatum/nucleus accumbens.⁶ This is because dopamine is taken up nonselectively by norepinephrine transporters in the prefrontal cortex.⁷ Atomoxetine may act by these indirect mechanisms to enhance dopamine D₁ receptor activity in the prefrontal cortex.³ Atomoxetine is advantageous in comparison to other stimulants because of its longer duration of action, lower risk of rebound symptoms, lower risk of induction of tics or psychosis, and lack of abuse potential.⁸ Its proposed therapeutic role in schizophrenia needs systematic evaluation in controlled trials.

The authors report no financial affiliation or relationship relevant to the subject of this letter.

REFERENCES

1. Bowie CR, Harvey PD. Cognition in schizophrenia: impairments, determinants, and functional importance. *Psychiatr Clin North Am* 2005;28:613–633
2. Faraone SV, Biederman J, Spencer T, et al. Atomoxetine and Stroop task performance in adult attention-deficit/hyperactivity disorder. *J Child Adolesc Psychopharmacol* 2005;15:664–670
3. Friedman JI, Stewart DG, Gorman JM. Potential noradrenergic targets for cognitive enhancement in schizophrenia. *CNS Spectr* 2004;9:350–355
4. Kelsey DK, Sumner CR, Casat CD, et al. Once-daily atomoxetine treatment for children with attention-deficit/hyperactivity disorder, including an assessment of evening and morning behavior: a double-blind, placebo-controlled trial. *Pediatrics* 2004;114:E1–E8

5. Quitkin FM, Rabkin JD, Markowitz JM, et al. Use of pattern analysis to identify true drug response: a replication. *Arch Gen Psychiatry* 1987;44:259–264
6. Bymaster FP, Katner JS, Nelson DL, et al. Atomoxetine increases extracellular levels of norepinephrine and dopamine in prefrontal cortex of rat: a potential mechanism for efficacy in attention deficit/hyperactivity disorder. *Neuropsychopharmacology* 2002;27:699–711
7. Tanda G, Pontieri FE, Frau R, et al. Contribution of blockade of the noradrenaline carrier to the increase of extracellular dopamine in the rat prefrontal cortex by amphetamine and cocaine. *Eur J Neurosci* 1997;9:2077–2085
8. Adler AL, Chua CH. Management of ADHD in adults. *J Clin Psychiatry* 2002;63(suppl 12):29–35

Naren P. Rao, M.B.B.S.
Ganesan Venkatasubramanian, M.B.B.S., M.D.
Bangalore N. Gangadhar, M.B.B.S., M.D.
 Department of Psychiatry
 National Institute of Mental Health & Neurosciences
 Bangalore, India

A Case of Olanzapine-Induced Gestational Diabetes Mellitus in the Absence of Weight Gain

Sir: Second-generation antipsychotics have been implicated in the development of obesity, diabetes mellitus, and insulin resistance. Pregnancy increases the risk for insulin resistance, sometimes resulting in gestational diabetes mellitus. We describe a case of a woman with bipolar disorder who developed gestational diabetes in the absence of significant weight gain while treated with olanzapine during 2 pregnancies.

Case report. Ms. A, a 38-year-old nulliparous Japanese woman with a history of bipolar disorder type II based on DSM-IV criteria, presented to the outpatient psychiatry clinic in 2004 for prenatal counseling. She denied personal or family history of diabetes. Her symptoms were controlled with lithium 900 mg, olanzapine 2.5 mg, and lamotrigine 350 mg daily. Conception occurred 3 months later.

Lithium was discontinued at 5 weeks' gestation. Lamotrigine 350 mg daily was continued throughout pregnancy and postpartum. At week 24, olanzapine was increased from 2.5 to 5.0 mg/day due to hypomanic symptoms.

A glucola* at 4 weeks' gestation (122 mg/dL) and a fasting blood glucose level at 16 weeks (87 mg/dL) were within normal limits. An oral glucose tolerance test (OGTT) at 25 weeks revealed hyperglycemia postingestion at 1 hour (182 mg/dL) and 2 hours (162 mg/dL). Gestational diabetes was diagnosed and managed via dietary changes.

Full-term vaginal delivery occurred at 40 weeks. The infant's weight at 3450 grams (7.6 lb) and Apgar scores of 9/9 were within normal limits. The patient's prepartum body mass index (BMI) was 20 kg/m² and her postpartum BMI was 21 kg/m², both within the normal range.

In the first year postpartum, the olanzapine dose of 5 mg/day was steadily increased, due to hypomanic symptoms, up to 15 mg/day. The patient reported elevated fasting blood glucose levels from finger sticks ranging from 95 mg/dL to 112 mg/dL†; however, fasting serum blood glucose levels were within

normal limits. At 11 months postpartum, elevated triglycerides (185 mg/dL) and a low high-density lipoprotein level (35 mg/dL) were noted, with a triglycerides/high-density lipoprotein ratio of 5.2, suggestive of insulin resistance.¹

Twenty months postpartum, the patient became pregnant while treated with lamotrigine 400 mg/day and olanzapine 15 mg/day. At 10 weeks' gestation, she was again diagnosed with gestational diabetes.

This patient had no history of weight gain or diabetes on olanzapine treatment (2.5 mg) prior to pregnancy or postpartum. However, the development of gestational diabetes in the latter half of her first pregnancy, new-onset hypertriglyceridemia and dyslipidemia postpregnancy, and recurrence of gestational diabetes in her second pregnancy are indicative of impaired glucose tolerance and insulin resistance.

Risk factors for the development of gestational diabetes include higher-than-normal body weight, maternal age > 25 years, non-Caucasian ethnicity, and family history of diabetes.² Gestational diabetes has been associated with increased risk for recurrence in future pregnancies.³

This patient had risk factors for gestational diabetes, including age and Asian ethnicity. It is unclear if the abnormalities in glucose metabolism during pregnancy and postpartum were manifestations of underlying insulin resistance or were exacerbated by olanzapine. Elevated glucose values occurred after olanzapine dose increases, suggesting that olanzapine might have played an etiologic role. Future studies are needed to elucidate the relationship between medications and pregnancy in the development of impaired glucose tolerance.

Dr. Rasgon has received grant/research support from Abbott, Forest, GlaxoSmithKline, and Wyeth-Ayerst; is on the advisory boards for GlaxoSmithKline and Wyeth-Ayerst; and currently receives or has received speaker honoraria from Abbott, Bristol-Myers Squibb, Forest, GlaxoSmithKline, and Pfizer. Dr. Vemuri reports no financial affiliation or other relationship relevant to the subject of this letter.

REFERENCES

1. McLaughlin T, Reaven G, Abbasi F, et al. Is there a simple way to identify insulin-resistant individuals at increased risk of cardiovascular disease? *Am J Cardiol* 2005;96:399–404
2. American Diabetes Association. Diagnosis and classification of diabetes mellitus. *Diabetes Care* 2004;27(suppl 1):S5–S10
3. MacNeill S, Dodds L, Hamilton DC, et al. Rates and risk factors for recurrence of gestational diabetes. *Diabetes Care* 2001;24:659–662

Mytilee P. Vemuri, M.D.
Natalie L. Rasgon, M.D., Ph.D.

Department of Psychiatry and Behavioral Sciences
 Stanford University
 Stanford, California

Correction

In the article "Teratogenicity and Anticonvulsants: Lessons From Neurology to Psychiatry" by Adele Casals Viguera, M.D., et al. (2007, Supplement 9, pp. 29–33), under "North American Antiepileptic Pregnancy Registry" on page 31, the observed prevalence of major malformations in a total of 564 children exposed to lamotrigine monotherapy was incorrectly reported from reference 16 as 5 cases (2.7%). The correct prevalence is 15 cases (2.7%). The online version of the article has been corrected.

*Screening test for gestational diabetes consisting of a 50-g glucose ingestion followed by a 1-hour postprandial glucose test.

†2004 ADA guidelines consider fasting blood glucose above 100 mg/dL to be in the "impaired fasting glucose" range.