

Structural and Functional Brain Changes in Posttraumatic Stress Disorder

David J. Nutt, M.D., Ph.D., and Andrea L. Malizia, M.D., Ph.D.

Posttraumatic stress disorder (PTSD) is a highly disabling condition that is associated with intrusive recollections of a traumatic event, hyperarousal, avoidance of clues associated with the trauma, and psychological numbing. The field of neuroimaging has made tremendous advances in the past decade and has contributed greatly to our understanding of the physiology of fear and the pathophysiology of PTSD. Neuroimaging studies have demonstrated significant neurobiologic changes in PTSD. There appear to be 3 areas of the brain that are different in patients with PTSD compared with those in control subjects: the hippocampus, the amygdala, and the medial frontal cortex. The amygdala appears to be hyperreactive to trauma-related stimuli. The hallmark symptoms of PTSD, including exaggerated startle response and flashbacks, may be related to a failure of higher brain regions (i.e., the hippocampus and the medial frontal cortex) to dampen the exaggerated symptoms of arousal and distress that are mediated through the amygdala in response to reminders of the traumatic event. The findings of structural and functional neuroimaging studies of PTSD are reviewed as they relate to our current understanding of the pathophysiology of this disorder.

(J Clin Psychiatry 2004;65[suppl 1]:11-17)

Posttraumatic stress disorder (PTSD) is a chronic, debilitating condition in which memories of traumatic events become uncontrollable, intrusive, and disabling. An understanding of the neurobiology of the response to trauma is key to the development of preventive and therapeutic interventions for patients with PTSD. Posttraumatic stress disorder has been studied using different neuroimaging techniques that provide a view of the structural and functional changes in the living brain. Neuroimaging studies have been useful in generating hypotheses on the neurobiology of normative human responses to trauma and of pathologic responses in patients with PTSD. The purpose of this article is to review current understanding of the pathophysiology of PTSD as informed by the findings of neuroimaging studies.

From the Psychopharmacology Unit, University of Bristol, Bristol, United Kingdom.

The International Consensus Group on Depression and Anxiety held the meeting "Update on Posttraumatic Stress Disorder," July 11-12, 2002, in Adare, County Limerick, Ireland. The Consensus Meeting was supported by an unrestricted educational grant from GlaxoSmithKline.

Dr. Malizia has served as a consultant to Neurosearch, received grant/research support from Wyeth and Lilly and honoraria from Pfizer, and served on the speakers or advisory boards for Bristol-Myers, Organon, and Pierre Fabre.

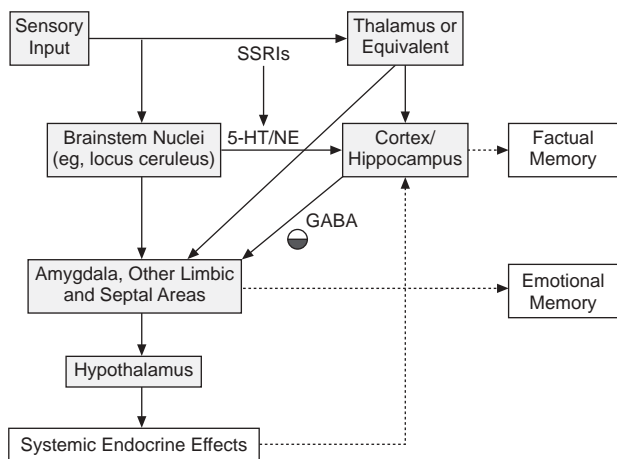
*Corresponding author and reprints: David J. Nutt, M.D., Ph.D., Psychopharmacology Unit, School of Medical Sciences, University of Bristol, Dorothy Hodgkin Building, Whitson Street, Bristol BS1 3NY, UK
(e-mail: david.j.nutt@bristol.ac.uk).*

NORMATIVE RESPONSE TO TRAUMA AND HYPOTHESES OF BRAIN DYSFUNCTION IN PTSD

The locus ceruleus and higher brain areas, such as the thalamus, are involved in the gating of sensory input and are critical to the experience of trauma. Fear, which is a normative response to a traumatic event or other threatening situation, involves activation of the hypothalamic-pituitary-adrenal (HPA) axis. Stimulation of the hypothalamus by either the thalamic, limbic, or locus ceruleus circuits activates the stress response, resulting in release of corticotropin-releasing factor and other neuroendocrine mediators.

The emotional and somatic contents of memories are associated via the amygdala; this process is modulated by serotonin and norepinephrine, and is thus influenced by output from nuclei regulating ascending aminergic transmission, such as the locus ceruleus (Figure 1). Other factual contents of the memory, including associated cues, are registered in the cortex and hippocampus. In nonpathological responses to trauma (as in acute stress reactions), the capacity of various stimuli to trigger fear or alerting responses decreases with time, and little or no dissociation is experienced for the index event. In pathological states, however, dysregulation in the processing of sensory input and memories is believed to contribute to the pathophysiology of PTSD.¹ This abnormal process includes continued dissociative experiences and inappropriate generalized vigilance.

Figure 1. Brain Pathways That Process Responses to Stress^a



^aAdapted with permission from Nutt.¹
 Abbreviations: GABA = γ -aminobutyric acid, 5-HT = serotonin, NE = norepinephrine, SSRIs = selective serotonin reuptake inhibitors.

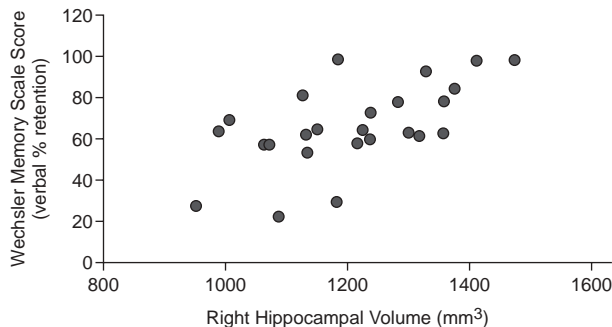
The medial prefrontal cortex modulates cognitive control of the anxiety response and is probably essential for habituation in normative stress reactions. Detail of medial prefrontal influence on other brain areas is still somewhat uncertain, but it is likely that its input into limbic structures decreases their responsivity. However, as stress or anxiety increase, this mechanism may become impaired, resulting in unmodified limbic activity and thus exaggerated responses. In this model, anxiety occurs when the emotional circuits that are mediated through the amygdala override prefrontal cortex behavioral controls.² At a behavioral level, this seems to be confirmed in PTSD as patients with this disorder exhibit slowed extinction after fear conditioning.³

Further dyscontrol may result from stress-induced brain damage. Studies in animal models of stress suggest that experimentally induced stressors result in structural and functional damage to brain regions, including the hippocampus.^{4,5} It has been postulated that hippocampal damage disrupts the normal negative feedback of the HPA axis, resulting in excessive exposure to cortisol and related cellular toxicity. These hypotheses are as yet unproven and are the basis for an active ongoing field of study.

STRUCTURAL IMAGING STUDIES IN PTSD

Structural neuroimaging studies in PTSD allow the testing of hypotheses of an association between PTSD and loss of gray matter. Finding such a loss speaks to either neurotoxic consequences of the condition or identification of predisposing factors for the development of PTSD. Volumetric or quantitative magnetic resonance imaging (MRI)

Figure 2. Relation Between Verbal Memory and Right Hippocampal Volume in 26 Combat Veterans With Posttraumatic Stress Disorder (PTSD)^a



^aReprinted with permission from Bremner et al.⁷ There was a significant correlation between deficits in verbal memory, as measured by a lower score on the percent retention subscale of the logical component of the Wechsler Memory Scale, and smaller right hippocampal volume ($r = 0.64$, $df = 20$, $p < .05$).

studies allow such visualization of gross structural abnormalities and the measurement of brain structure volumes.⁶

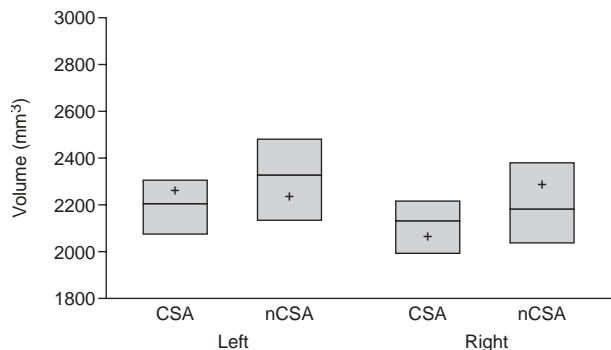
Hippocampal Volume

Most findings of volumetric MRI studies in adult victims of trauma or adults with a history of childhood trauma demonstrate that patients with PTSD have reduced hippocampal volume by the time they take part in such imaging studies.⁷⁻¹⁰ In contrast, a small study of children with PTSD did not find shrinkage of the hippocampus,¹¹ and Bonne and coworkers¹² demonstrated that subjects with PTSD did not differ from those without PTSD in hippocampal volume (right or left) at 1 week or 6 months after a severe traumatic event. Equally, there was no reduction in hippocampal volume in the subjects with PTSD in this study between 1 week and 6 months.

Reductions in hippocampal volume may be related to the neurotoxic effects of elevated concentrations of cortisol, which occur following stress,^{13,14} although many studies have shown that patients with PTSD are hypocortisolemic. The hippocampus is involved in memory, and patients with PTSD have been shown to have deficits in short-term, declarative memory.¹⁵⁻¹⁷ In a study of 26 combat veterans with PTSD, Bremner and associates⁷ demonstrated that mean right hippocampal volumes were 8% smaller compared with those of healthy veterans without PTSD. Mean reductions in left hippocampal volumes (3.8%) were not significantly different from controls. Of note, short-term verbal memory deficits in patients with combat-related PTSD correlated with smaller right-sided hippocampal volumes (Figure 2).

Using quantitative MRI, the hippocampal volumes of 21 adult women with histories of severe childhood sexual abuse (15 of whom fulfilled DSM-IV criteria for PTSD)

Figure 3. Magnetic Resonance Imaging (MRI)-Derived Hippocampal Volumes in 21 Women With Severe Childhood Sexual Abuse (CSA) and 21 Nonabused Women (nCSA)^a



^aReprinted with permission from Stein et al.⁹ Boxes include the interquartile range (i.e., 25th to 75th percentile), with the horizontal line within the box indicating the group median (+ indicates the group mean).

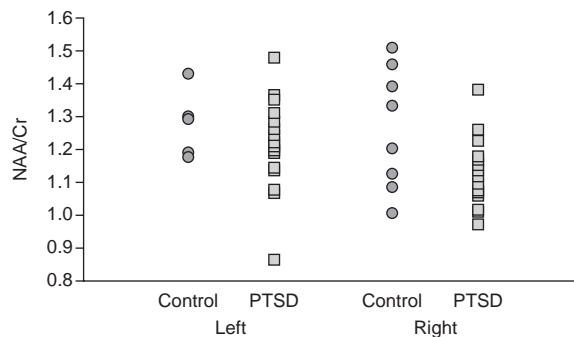
were compared with nonabused matched control subjects.⁹ Left hippocampal volumes were significantly lower in women with histories of abuse compared with those of nonabused controls. Right hippocampal volumes were also lower in women with histories of abuse, but between-group differences were not statistically significant (Figure 3). Reductions in left-sided hippocampal volume correlated with severity of dissociative symptoms, but not with history of alcohol use, abuse characteristics, or memory.

In another study of adult survivors of childhood abuse, significant reductions were noted in left-side hippocampal volume (12%) compared with healthy controls who were matched for alcohol abuse and other factors. There were no between-group differences in the size of the amygdala, temporal lobe, or caudate. In addition, there was no relationship between hippocampal volume reductions and delayed recall on the Wechsler Memory Scale.¹⁸ Villarreal and associates,¹⁰ however, found bilateral reductions in hippocampal volume and a generalized white matter atrophy. PTSD and depression scores correlated negatively with left hippocampal volume, but PTSD scores were a better predictor of total hippocampal volumes.

Based on these findings, it is possible to speculate that unilateral structural differences in the hippocampus of persons who have been exposed to severe trauma may be associated with specific forms of functional impairment. For example, reductions in right hippocampal volume may be associated with memory deficits, and left-sided damage may be linked to increased symptoms of dissociation. An alternative explanation is that reductions in hippocampal volume are bilateral, but that smaller studies are biased to detect unilateral damage.

Although these changes may be germane to PTSD, the fact that they do not occur in children and the observation

Figure 4. Peak-Area Ratio *N*-Acetyl-L-aspartic Acid/Creatine (NAA/Cr) for Right and Left Medial Temporal Lobes in 21 Patients With Combat-Related Posttraumatic Stress Disorder (PTSD) and 8 Age-Matched Control Veterans Without PTSD^a



^aReprinted with permission from Freeman et al.¹⁹

that they may not occur in the first 6 months after a traumatic event may instead indicate that decreased hippocampal volume is an epiphenomenon associated with prolonged disease or other related factors, such as increased alcohol use. Further studies are thus needed to exclude the role of confounding factors, such as psychiatric comorbidity (e.g., depression) and substance abuse. Until a number of longer-term longitudinal studies are conducted, it is not possible to determine if the changes in hippocampal volume seen in these studies are concomitant with the development of PTSD or are a response to some associated features or if the observed structural changes represent the expression of a pre-existing vulnerability to PTSD after exposure to trauma.^{6,13}

Hippocampal Neuronal Loss

Freeman and associates¹⁹ used proton magnetic resonance spectroscopy (MRS) to determine if combat-related PTSD was associated with right-sided neuronal loss or damage. Proton MRS measures specific compounds in the brain, such as *N*-acetyl-L-aspartic acid (NAA), choline, creatine (Cr), and myoinositol, as markers for neuronal density. Reduction in the signal of a target compound indicates neuronal loss or damage. Freeman and colleagues¹⁹ compared the proton MRS scans of 21 combat veterans with PTSD with those from 8 control veterans without PTSD. Compared with controls, the patients with PTSD demonstrated significantly lower ratios of NAA/Cr for the right versus left medial temporal lobe, indicating neuronal loss in the hippocampus (Figure 4). In a small study, Villarreal and associates²⁰ also found reduced hippocampal NAA and Cr in PTSD, but on the left side as opposed to the right side.

These findings support the hypothesis that PTSD is associated with structural damage to the hippocampus. Lateralization may be related to specific symptom patterns

and may speak to an interaction between abnormal neuronal activity and an altered endocrine milieu. This is highly speculative, as our understanding of the pathophysiology of PTSD and related structural changes in the brain is in its infancy. A true understanding of the organic changes that are associated with PTSD will not be achieved until structural changes in the entire brain are measured in healthy subjects and in the entire spectrum of psychiatric disorders. Longitudinal studies related to symptom patterns also are essential in this area.

FUNCTIONAL NEUROIMAGING STUDIES IN PTSD

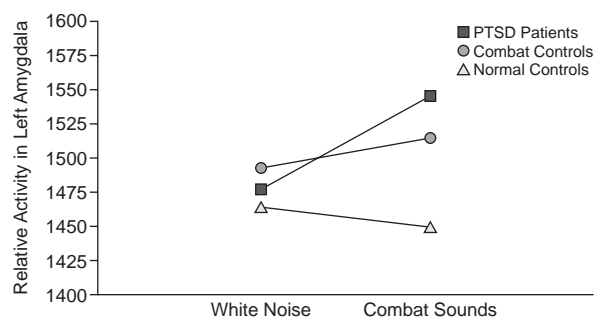
Positron emission tomography (PET), single photon emission computed tomography (SPECT), and functional MRI (fMRI) have shed light on the neuronal activity of the brain and have augmented the findings of animal model, neuroendocrine, and postmortem studies in elucidating function and pathology. PET and SPECT measure dynamic patterns of brain capillary perfusion and glucose metabolism as markers for neuronal activity. In addition, PET and SPECT are used to measure neurotransmitter receptors and transporters via radio-labeled ligands or precursors of neurotransmitters. Functional MRI determines changes in regional cerebral blood oxygenation that are associated with neuronal activity.²¹

PTSD is a suitable illness for functional neuroimaging studies because symptoms can be dependably provoked by certain stimuli. Most functional imaging studies in PTSD compare symptomatic states with neutral or baseline states. Experimentally, PTSD symptoms have been evoked by script-driven imagery, sounds (e.g., combat sounds), images, virtual-reality devices, cognitive activation paradigms, and administration of anxiogenic pharmacologic agents.

This is an emerging field of endeavor, and the findings of functional neuroimaging studies in PTSD are interesting, but somewhat inconsistent. Due to the heterogeneous nature of trauma associated with PTSD, it can be difficult to evoke emotional responses in control subjects that match the symptom responses in patients with PTSD. Future studies will benefit by inclusion of larger sample sizes, multicenter sites, and hypothesis-driven designs that utilize identical methods of symptom provocation and neuroimaging.

Of particular interest are imaging studies involving combat veterans or women with histories of childhood sexual abuse. In these studies, fMRI, PET, or SPECT were used to measure the effects of script-driven imagery or cognitive activation in patients and trauma-matched controls with and without PTSD.²²⁻²⁹ The findings of these studies implicate the paralimbic structures, the amygdala, and the cingulate cortex in pathophysiologic responses to trauma.

Figure 5. Increased Relative Activity in Left Amygdala in Combat Veterans With Posttraumatic Stress Disorder (PTSD) but not in Veterans Without PTSD or Normal Controls in Response to Neutral and Combat-Related Sounds^a



^aReprinted with permission from Liberzon et al.²⁴

Paralimbic Cortex

In one early, uncontrolled study of combat veterans, Rauch and coworkers²⁵ used PET and script-driven imagery of combat trauma to demonstrate increased regional cerebral blood flow (rCBF) in the right-side visual cortex and in the limbic and paralimbic structures. In a later study,²⁷ task-related increases in cerebral perfusion in areas such as the orbitofrontal cortex and anterior temporal poles were also shown in healthy controls presented with the same material. Nevertheless, such increases remained larger in PTSD patients.

Amygdala

In a follow-up study of combat veterans with PTSD and control veterans without PTSD who visualized images of combat scenarios, rCBF increased in the ventral anterior cingulate gyrus and right amygdala in subjects with PTSD, but not in healthy controls.²⁸ However, such increases were not seen on direct viewing of the images when patients with PTSD showed decreases in Broca's area, a finding replicated in some other studies. Liberzon and colleagues²⁴ used SPECT scanning of combat veterans with and without PTSD and healthy control subjects to show that listening to neutral "white noise" sounds did not activate the amygdala. However, in response to combat sounds, only patients with PTSD demonstrated marked activation of the left amygdala (Figure 5). Pissioti and colleagues³⁰ also described right amygdala, periaqueductal, sensory cortex, and cerebellar activation following exposure to combat sounds.

It is of interest that amygdala activation has not been reported in any of the paradigms involving direct visual stimulation or autobiographical scripts, but that it seems to be more prominent in situations where more indirect or partial stimuli are presented. In an elegant experiment, Rauch's group³¹ demonstrated that patients with PTSD responded to the presentation of masked fearful faces with

greater amygdala activation than controls. The fact that this response was triggered by masked stimuli demonstrates that this process is “automatic” and not linked to “conscious” control.

Taken together with the other activation studies, these findings may speak to PTSD patients showing a decreased threshold for amygdala activation and thus an abnormal generation of strong emotional associations with sensory stimuli. This abnormal mechanism may relate to the chronicity of PTSD as an increasing number of new sensory triggers are linked with vivid memories of the traumatic events.

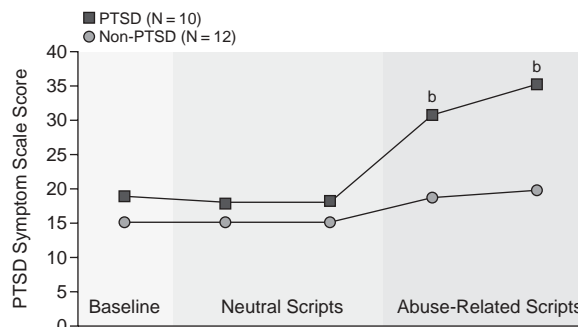
Cingulate and Medial Prefrontal Cortex

Functional neuroimaging also has been used in studies of combat veterans or women who were sexually abused as children to assess whether higher brain structures are involved in controlling symptomatic responses in a “top-down” manner. Patients with PTSD were compared with trauma-matched controls without PTSD. PET scanning was used in one study of combat veterans to measure neural correlates associated with viewing traumatic sounds and images.²² In another study of combat veterans, fMRI was used to measure changes in activation of the anterior cingulate cortex in response to a cognitive activation model.²⁶ Patients with PTSD demonstrated decreased activity in the medial prefrontal cortex²² or rostral anterior cingulate cortex²⁶ compared with that in controls. In contrast, another series of SPECT studies of combat veterans did not differentiate patients with PTSD from control subjects on the basis of anterior cingulate or medial prefrontal cortex activation,²⁴ and although they found increased medial prefrontal cortex activation, this had no correlation with symptoms.²⁹

Two studies of women with histories of childhood sexual abuse used PET scanning to measure changes in rCBF in response to script-driven imagery of neutral and abuse-related events.^{23,27} Patients with PTSD exhibited significantly greater symptoms compared with control subjects while listening to scripts that were related to their sexual abuse experiences (Figure 6). Script-driven imagery prompted memories of the abuse experiences in all subjects and resulted in increased activation of the posterior cingulate and motor cortex but no activation of the medial prefrontal cortex or anterior cingulate in women with PTSD compared with controls.²³ Similarly, Shin and associates²⁷ found increased activation in the orbitofrontal cortex and anterior temporal poles in both patients with PTSD and control subjects. However, only patients with PTSD exhibited a failure to activate the left inferior frontal gyrus (i.e., Broca’s area) and the anterior cingulate gyrus.

The interpretation of data relating to medial prefrontal cortex is that patients fail to modulate neuronal activity in this area when experiencing anxiety and thus do not habituate to the stimuli. In contrast, understanding failure of

Figure 6. Posttraumatic Stress Disorder (PTSD) Symptom Scale Scores for Women With and Without PTSD at Baseline and During Readings of Neutral Scripts and Scripts Related to Their Childhood Sexual Abuse Experience^a



^aReprinted with permission from Bremner et al.²³

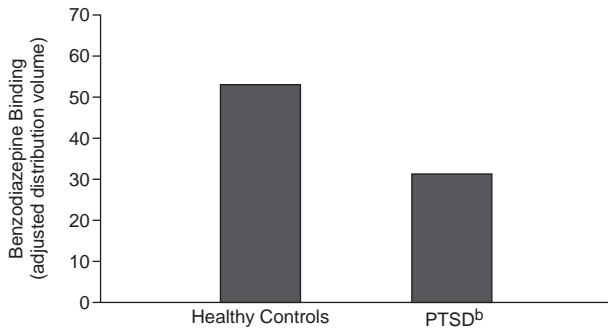
^bGroup-by-time interaction: $F = 7.88$; $df = 4,80$; $p < .01$.

activation in the anterior cingulate is more difficult, especially in light of early script-driven studies²⁵ that demonstrated increased activity in this area and the fact that many anxiety-provocation studies also show increased activity in this brain region. Possible confounds, such as greater regional anatomical variability, decreased novelty, or high baseline values are fully discussed by Shin and colleagues.²⁶

Ligand Neuroimaging

The use of ligand neuroimaging in PTSD is an emerging field of study. Growth of knowledge in this area of research is limited in part by the discovery of useful ligands or tracers. Animals exposed to chronic inescapable stressors exhibit global reductions in benzodiazepine receptor binding that is maximal in the frontal cortex and hippocampus,^{32,33} which suggests that changes in the benzodiazepine receptor may be related to symptoms of anxiety and PTSD. The radiolabeled tracer [¹²³I]-iomazenil has been used to image the central benzodiazepine receptor in patients with panic disorder.³⁴ In the first study of PTSD, Bremner and coworkers³⁵ used [¹²³I]-iomazenil and SPECT to measure changes in central benzodiazepine binding in combat veterans with PTSD and in healthy, matched control subjects. The distribution volume in the prefrontal cortex, which is a measure of benzodiazepine receptor binding, was 41% lower in patients with PTSD compared with controls (Figure 7). Between-group differences in benzodiazepine receptor binding in other areas of the brain were not observed. These findings could be interpreted to suggest that benzodiazepine receptors are down-regulated in PTSD. Alternatively, combat exposure could result in stress-related changes in the benzodiazepine receptor or in g-aminobutyric acid (GABA)-ergic neurotransmission in the prefrontal cortex. Another possible explanation is that persons with low levels of benzodiaze-

Figure 7. Benzodiazepine Receptor Binding in the Prefrontal Cortex of 13 Patients With Posttraumatic Stress Disorder (PTSD) and 13 Healthy Controls^a



^aReprinted with permission from Bremner et al.³⁵

^bSignificantly lower mean distribution volume in patients than in controls ($z = 3.56, p < .01$).

pine receptors are at greater risk for developing PTSD. To date, the final possible explanation of the atrophy of medial prefrontal cortex is not supported by volumetric MRI studies. However, it is possible that benzodiazepine receptor density is a more sensitive measure of interneuronal loss than gray matter measurements on MRI. Any of these explanations, however, speak again to a dysfunctional medial prefrontal cortex that may be unable to modulate inappropriate limbic activity. Additional studies are required to answer these questions.

CONCLUSION

Neuroimaging technology has enabled great advances in our understanding of the significant structural and functional changes that occur in patients with PTSD. MRI has demonstrated marked reductions in hippocampal volume in a heterogeneous population of adults with PTSD. Even greater progress has been achieved through the use of functional imaging techniques, such as PET, SPECT, and fMRI. Functional imaging studies that have used script-driven imagery and other methods of provoking re-experiencing symptoms of PTSD as well as studies using cognitive activation models have, for the most part, demonstrated a pattern of a hyperresponsive amygdala operating in the context of attenuated negative feedback from the medial prefrontal cortex and the anterior cingulate gyrus. These findings are believed to be salient to the pathophysiology of PTSD. The amygdala is involved in mediating negative emotions and physical symptoms associated with autonomic arousal. Failure of higher brain regions (e.g., prefrontal cortex) to extinguish conditioned fear responses may in part explain the symptomatology associated with PTSD.

How do the structural changes observed in the hippocampus relate to the functional changes in the amygdala

and cingulate cortex? We are not yet able to answer this pivotal question. Although functional neuroimaging studies have not yet demonstrated hyporesponsivity in the hippocampus, this structure also is believed to dampen amygdala activity. There is a large body of literature demonstrating marked reductions in hippocampal volume in patients with PTSD. Based on the findings of these studies, it could be speculated that a smaller, or somehow damaged, hippocampus is less able to control an overactive amygdala. Such hypotheses require controlled study in a functional neuroimaging trial in which the reduced volume of the hippocampus in patients with PTSD is shown to correlate with functional changes.

The use of neuroimaging techniques remains a cornerstone to our further understanding of the pathophysiology of PTSD. These tools also offer the hope of direct clinical application. Should a marker of brain structure or function definitely be correlated with PTSD, then it is feasible that neuroimaging could be used to identify persons at high risk or to confirm the diagnosis of this disorder. Alternatively, PET or SPECT could someday be used to determine which patients are likely to respond to a given treatment or to tailor treatment to individual patients. It is likely that the first clinical application of PET or SPECT will be related to the identification and design of new targets for therapeutic intervention.

REFERENCES

- Nutt DJ. The psychobiology of posttraumatic stress disorder. *J Clin Psychiatry* 2000;61(suppl 5):24–29
- Ninan PT. The functional anatomy, neurochemistry, and pharmacology of anxiety. *J Clin Psychiatry* 1999;60(suppl 22):12–17
- Orr SP, Metzger LJ, Lasko NB, et al. De novo conditioning in trauma-exposed individuals with and without posttraumatic stress disorder. *J Abnorm Psychol* 2000;109:290–298
- McEwen BS, Magarinos AM. Stress effects on morphology and function of the hippocampus. *Ann N Y Acad Sci* 1997;821:271–284
- Sapolsky R, Krey LC, McEwen BS. Prolonged glucocorticoid exposure reduces hippocampal cell number: implications for aging. *J Neurosci* 1985;5:1222–1227
- Pittman RK, Shin LM, Rauch SL. Investigating the pathogenesis of posttraumatic stress disorder with neuroimaging. *J Clin Psychiatry* 2001;62(suppl 17):47–54
- Bremner JD, Randall P, Scott TM, et al. MRI-based measurement of hippocampal volume in patients with combat-related posttraumatic stress disorder. *Am J Psychiatry* 1995;152:973–981
- Gurvits TV, Shenton ME, Hokama H, et al. Magnetic resonance imaging study of hippocampal volume in chronic, combat-related posttraumatic stress disorder. *Biol Psychiatry* 1996;40:1091–1099
- Stein MB, Koverola C, Hanna C, et al. Hippocampal volume in women victimized by childhood sexual abuse. *Psychol Med* 1997;27:951–959
- Villarreal G, Hamilton DA, Petropoulos H, et al. Reduced hippocampal volume and total white matter volume in posttraumatic stress disorder. *Biol Psychiatry* 2002;52:119–125
- De Bellis MD, Hall J, Boring AM, et al. A pilot longitudinal study of hippocampal volumes in pediatric maltreatment-related posttraumatic stress disorder. *Biol Psychiatry* 2001;50:305–309
- Bonne O, Brandes D, Gilboa A, et al. Longitudinal MRI study of hippocampal volume in trauma survivors with PTSD. *Am J Psychiatry* 2001;158:1248–1251
- Sapolsky RM. Glucocorticoids and hippocampal atrophy in neuropsychiatric disorders. *Arch Gen Psychiatry* 2000;57:925–935
- Virgin CE Jr, Ha TP, Packan DR, et al. Glucocorticoids inhibit glucose

- transport and glutamate uptake in hippocampal astrocytes: implications for glucocorticoid neurotoxicity. *J Neurochem* 1991;57:1422–1428
15. Bremner JD, Scott TM, Delaney RC, et al. Deficits in short-term memory in posttraumatic stress disorder. *Am J Psychiatry* 1993;150:1015–1019
 16. Sutker PB, Winstead DK, Galina ZH, et al. Cognitive deficits and psychopathology among former prisoners of war and combat veterans of the Korean conflict. *Am J Psychiatry* 1991;148:67–72
 17. Yehuda R, Keefe RS, Harvey PD, et al. Learning and memory in combat veterans with posttraumatic stress disorder. *Am J Psychiatry* 1995;152:137–139
 18. Bremner JD, Randall P, Vermetten E, et al. Magnetic resonance imaging-based measurement of hippocampal volume in posttraumatic stress disorder related to childhood physical and sexual abuse: a preliminary report. *Biol Psychiatry* 1997;41:23–32
 19. Freeman TW, Cardwell D, Karson CN, et al. In vivo proton magnetic resonance spectroscopy of the medial temporal lobes of subjects with combat-related posttraumatic stress disorder. *Magn Reson Med* 1998;40:66–71
 20. Villarreal G, Petropoulos H, Hamilton DA, et al. Proton magnetic resonance spectroscopy of the hippocampus and occipital white matter in PTSD: preliminary results. *Can J Psychiatry* 2002;47:666–670
 21. Nemeroff CB, Kilts CD, Berns GS. Functional brain imaging: twenty-first century phenology or psychobiological advance for the millennium? *Am J Psychiatry* 1999;156:671–673
 22. Bremner JD, Staib LH, Kaloupek D, et al. Neural correlates of exposure to traumatic pictures and sound in Vietnam combat veterans with and without posttraumatic stress disorder: a positron emission tomography study. *Biol Psychiatry* 1999;45:806–816
 23. Bremner JD, Narayan M, Staib LH, et al. Neural correlates of memories of childhood sexual abuse in women with and without posttraumatic stress disorder. *Am J Psychiatry* 1999;156:1787–1795
 24. Liberzon I, Taylor SF, Amdur R, et al. Brain activation in PTSD in response to trauma-related stimuli. *Biol Psychiatry* 1999;45:817–826
 25. Rauch SL, van der Kolk BA, Fisler RE, et al. A symptom provocation study of posttraumatic stress disorder using positron emission tomography and script-driven imagery. *Arch Gen Psychiatry* 1996;53:380–387
 26. Shin LM, Whalen PJ, Pitman RK, et al. An fMRI study of anterior cingulate function in posttraumatic stress disorder. *Biol Psychiatry* 2001;50:932–942
 27. Shin LM, McNally RJ, Kosslyn SM, et al. Regional cerebral blood flow during script-driven imagery in childhood sexual abuse-related PTSD: a PET investigation. *Am J Psychiatry* 1999;156:575–584
 28. Shin LM, Kosslyn SM, McNally RJ, et al. Visual imagery and perception in posttraumatic stress disorder. *Arch Gen Psychiatry* 1997;54:233–241
 29. Zubieta JK, Chinitz JA, Lombardi U, et al. Medial frontal cortex involvement in PTSD symptoms: a SPECT study. *J Psychiatr Res* 1999;33:259–264
 30. Pissiota A, Frans O, Fernandez M, et al. Neurofunctional correlates of posttraumatic stress disorder: a PET symptom provocation study. *Eur Arch Psychiatry Clin Neurosci* 2002;252:68–75
 31. Rauch SL, Whalen PJ, Shin LM, et al. Exaggerated amygdala response to masked facial stimuli in posttraumatic stress disorder: a functional MRI study. *Biol Psychiatry* 2000;47:769–776
 32. Weizman A, Weizman R, Kook KA, et al. Adrenalectomy prevents the stress-induced decrease in in vivo [3H]R015-1788 binding to GABAA benzodiazepine receptors in the mouse. *Brain Res* 1990;519:347–350
 33. Weizman R, Weizman A, Kook KA, et al. Repeated swim stress alters brain benzodiazepine receptors measured in vivo. *J Pharmacol Exp Ther* 1989;249:701–707
 34. Bremner JD, Innis RB, White T, et al. SPECT [I-123] iomazenil measurement of the benzodiazepine receptor in panic disorder. *Biol Psychiatry* 2000;47:96–106
 35. Bremner JD, Innis RB, Southwick SM, et al. Decreased benzodiazepine receptor binding in prefrontal cortex in combat-related posttraumatic stress disorder. *Am J Psychiatry* 2000;157:1120–1126

Questions and Answers

Question: It appears that most of the neuroimaging studies in PTSD are cross-sectional. Have longitudinal studies been conducted, and if so, what do the findings of these studies suggest?

Dr. Nutt: As we interpret neuroimaging studies in PTSD, we must keep in mind that correlations do not necessarily establish causal relationships. This is particularly true when linking the putative effects of stress to the findings of studies showing hippocampal volume reduction and functional changes in other brain regions in patients with PTSD. Until longitudinal or twin studies are conducted that demonstrate hippocampal shrinkage and/or functional changes in the amygdala and cingulate cortex occurring after exposure to trauma, we cannot know with certainty the role of observed changes in this disorder.

Question: Do you envision a clinical use for neuroimaging in the care of patients with PTSD?

Dr. Nutt: Currently, neuroimaging has not found a role in the clinical care of patients with PTSD. However, as the field evolves, we expect that neuroimaging could have several clinical applications. For example, if structural or functional brain changes are found to be antecedent to the development of PTSD, it is possible that at-risk patients could be identified prior to the development of syndromal PTSD. Ligand imaging studies also offer the hope of identifying specific targets for pharmacotherapy of PTSD. □